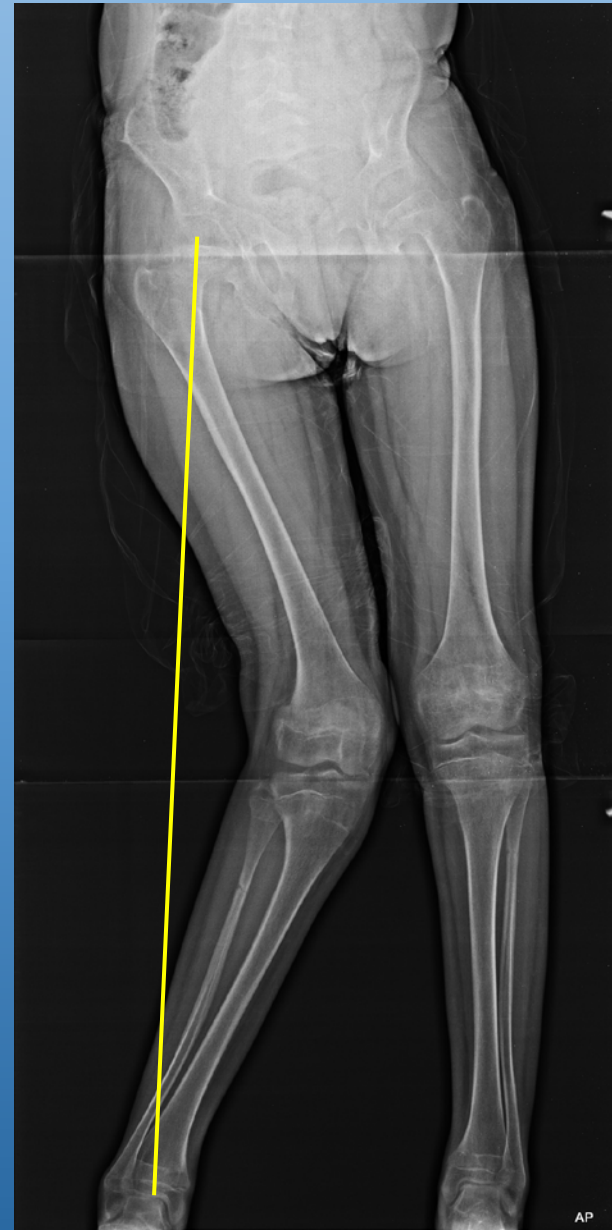
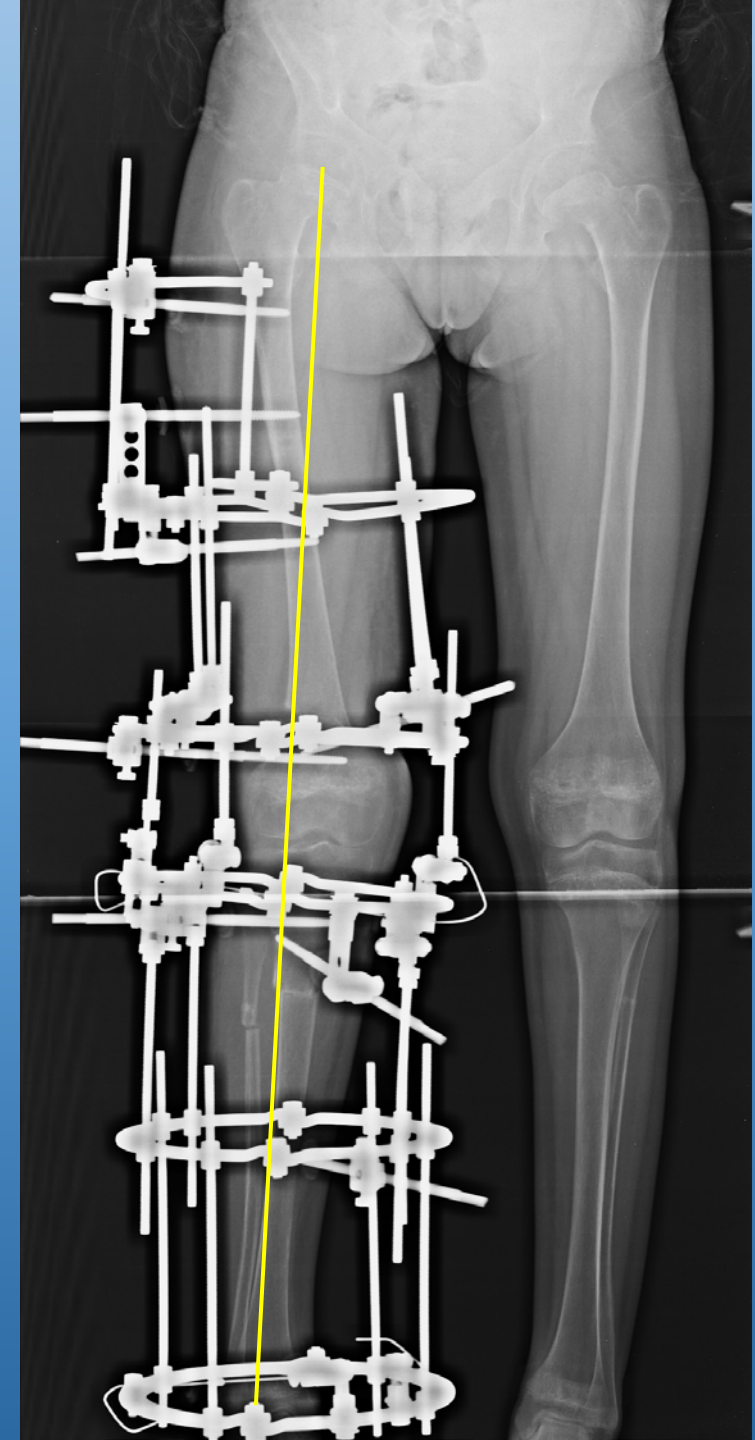


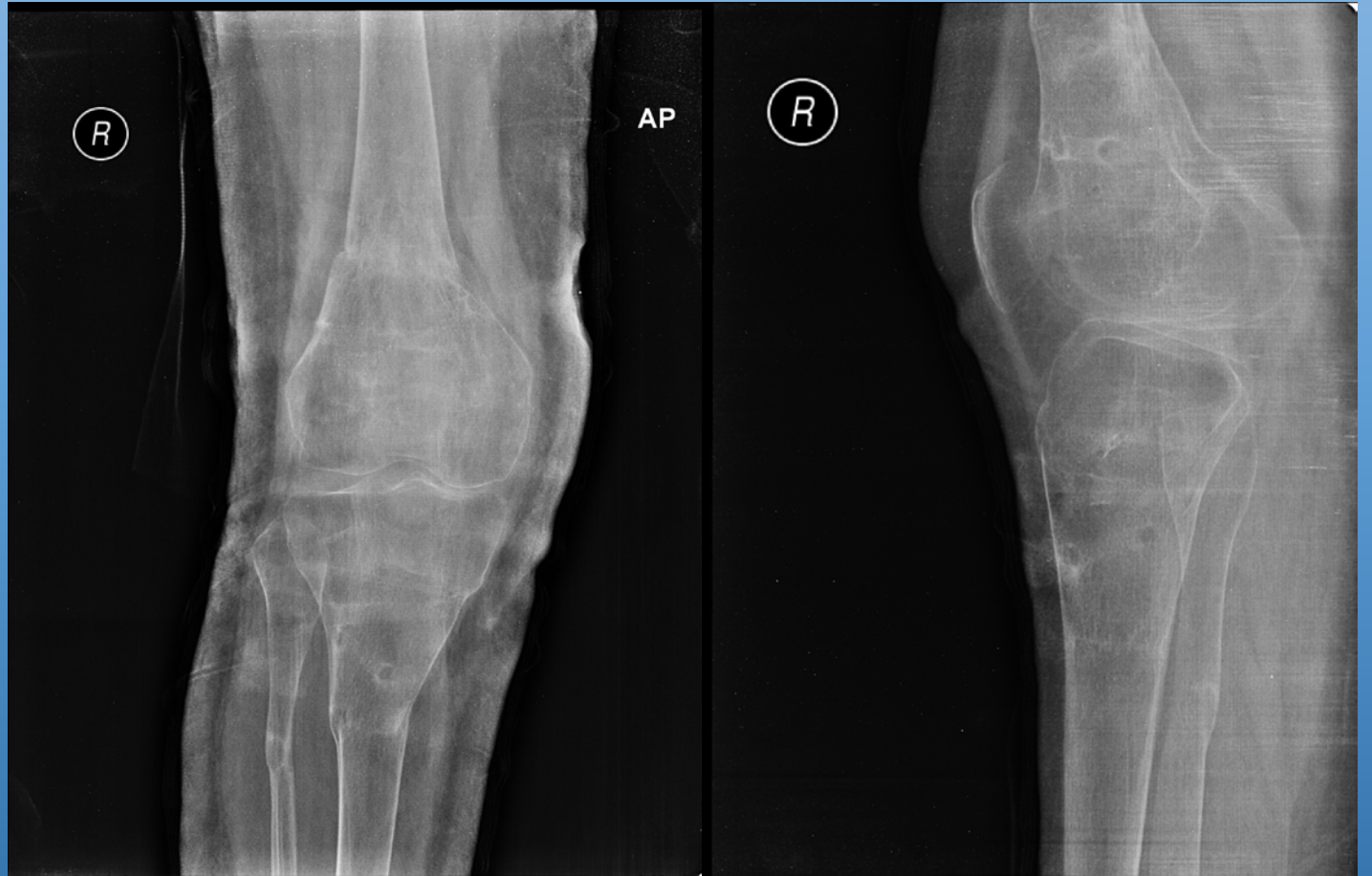- Young lady, 14 yrs
- R Genu Valgum



- Distal femoral & proximal tibial percutaneous osteotomy with hybrid Ilizarov fixator.



- after fixator removal.
- Notice the minimal lateral translation of distal femur and medial translation of distal tibial fragments to help correct mechanical axis by Rule 2.



- Full length x ray at latest follow up
- 10 months post op

