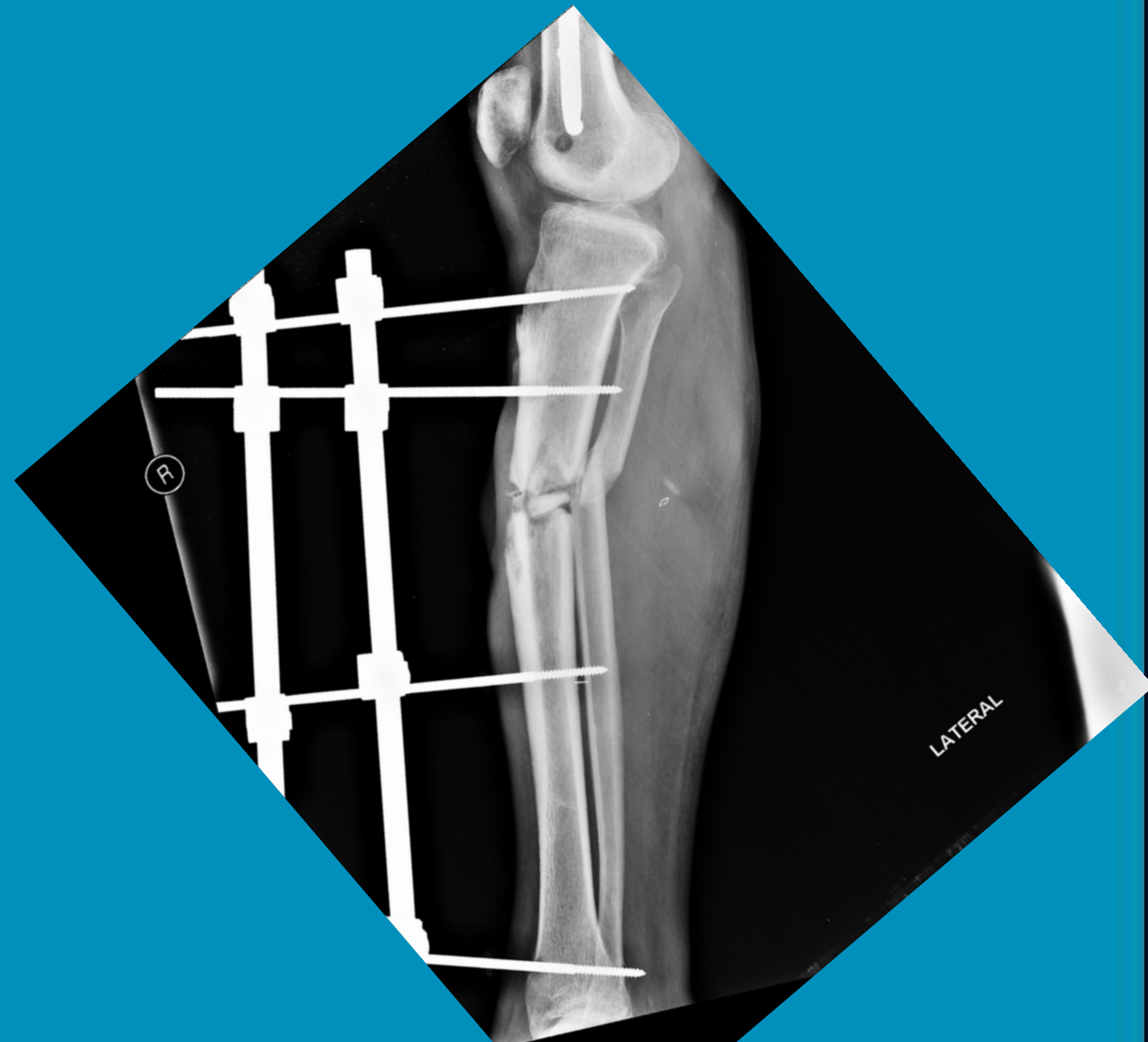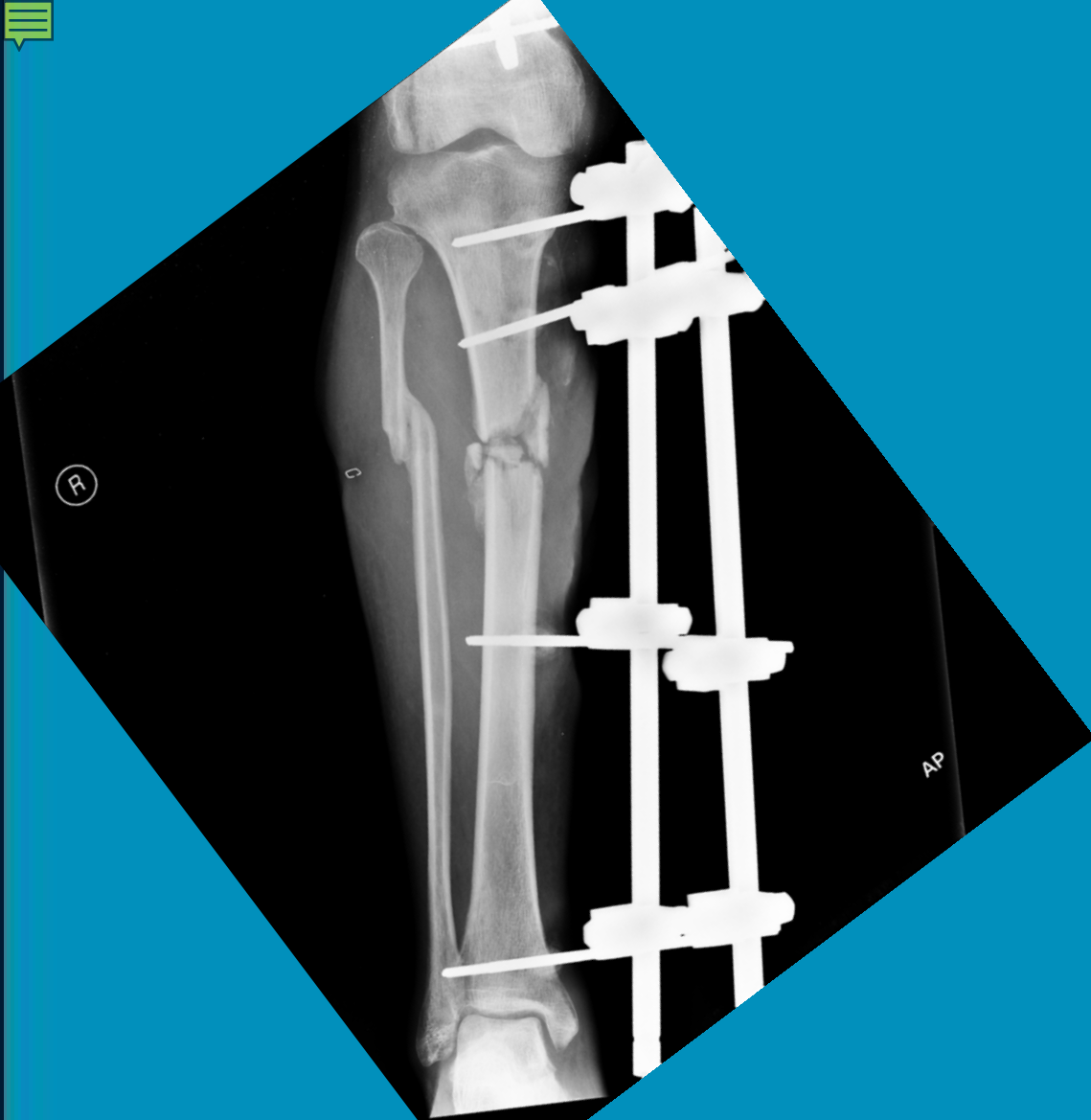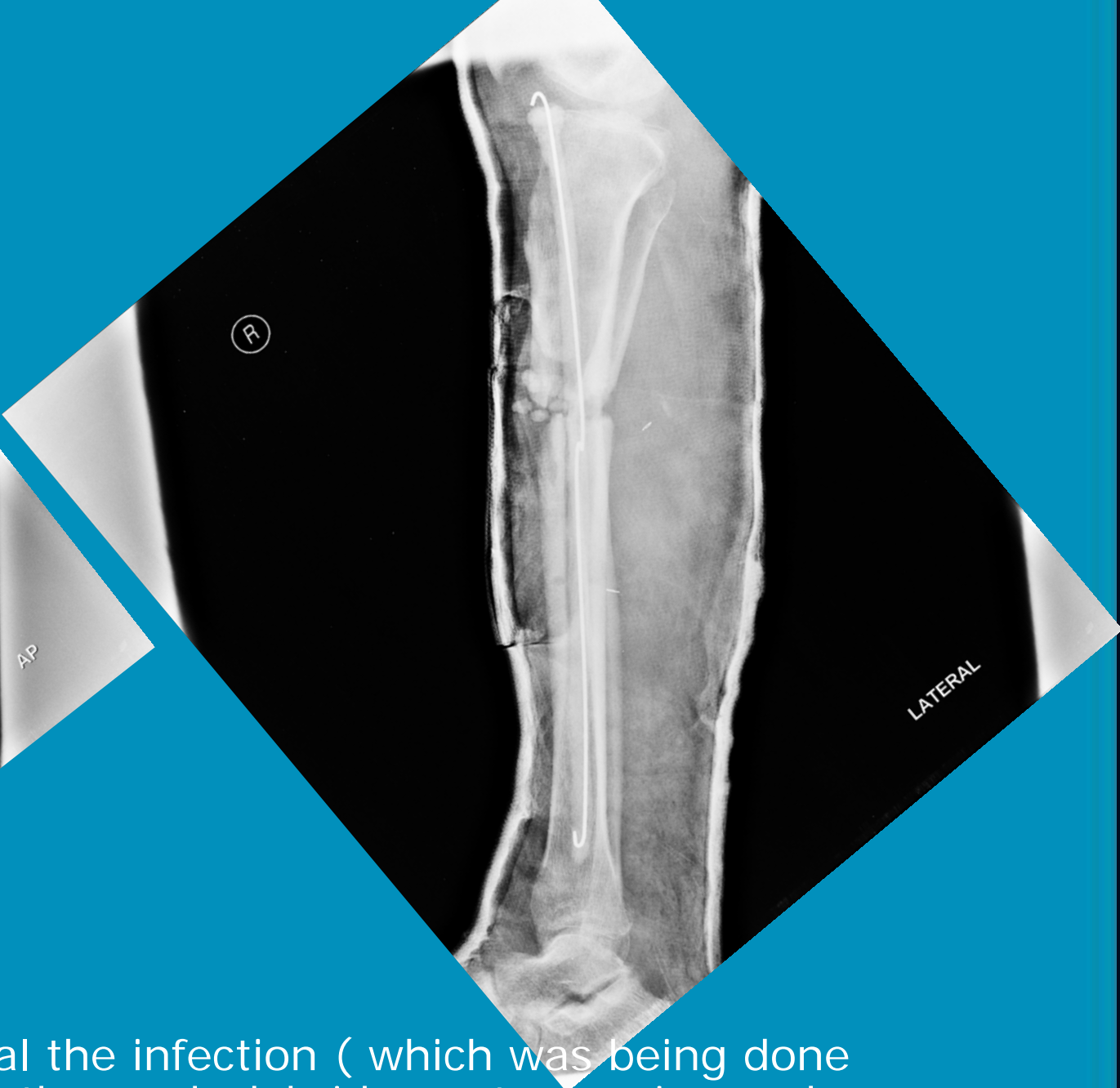
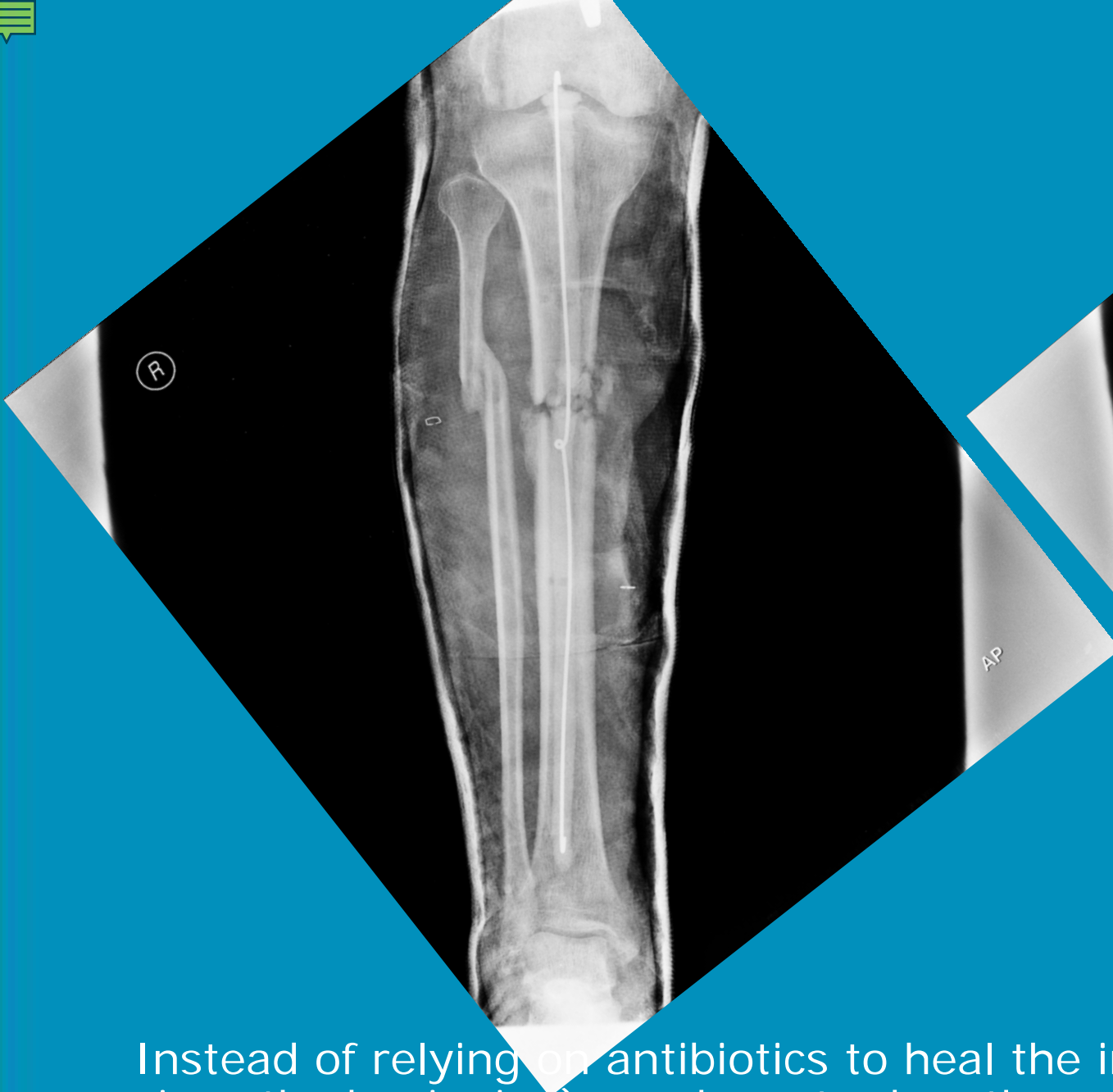
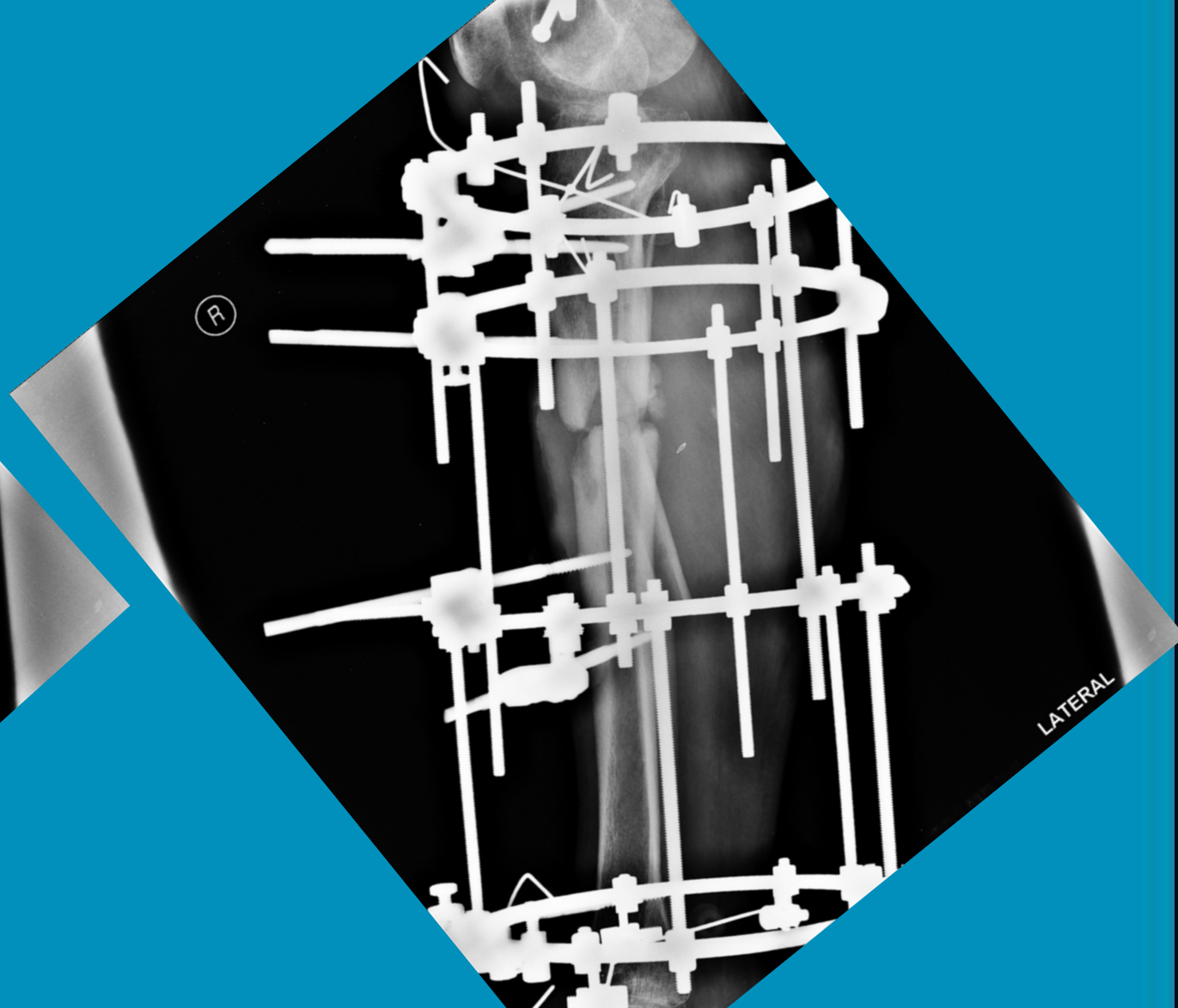
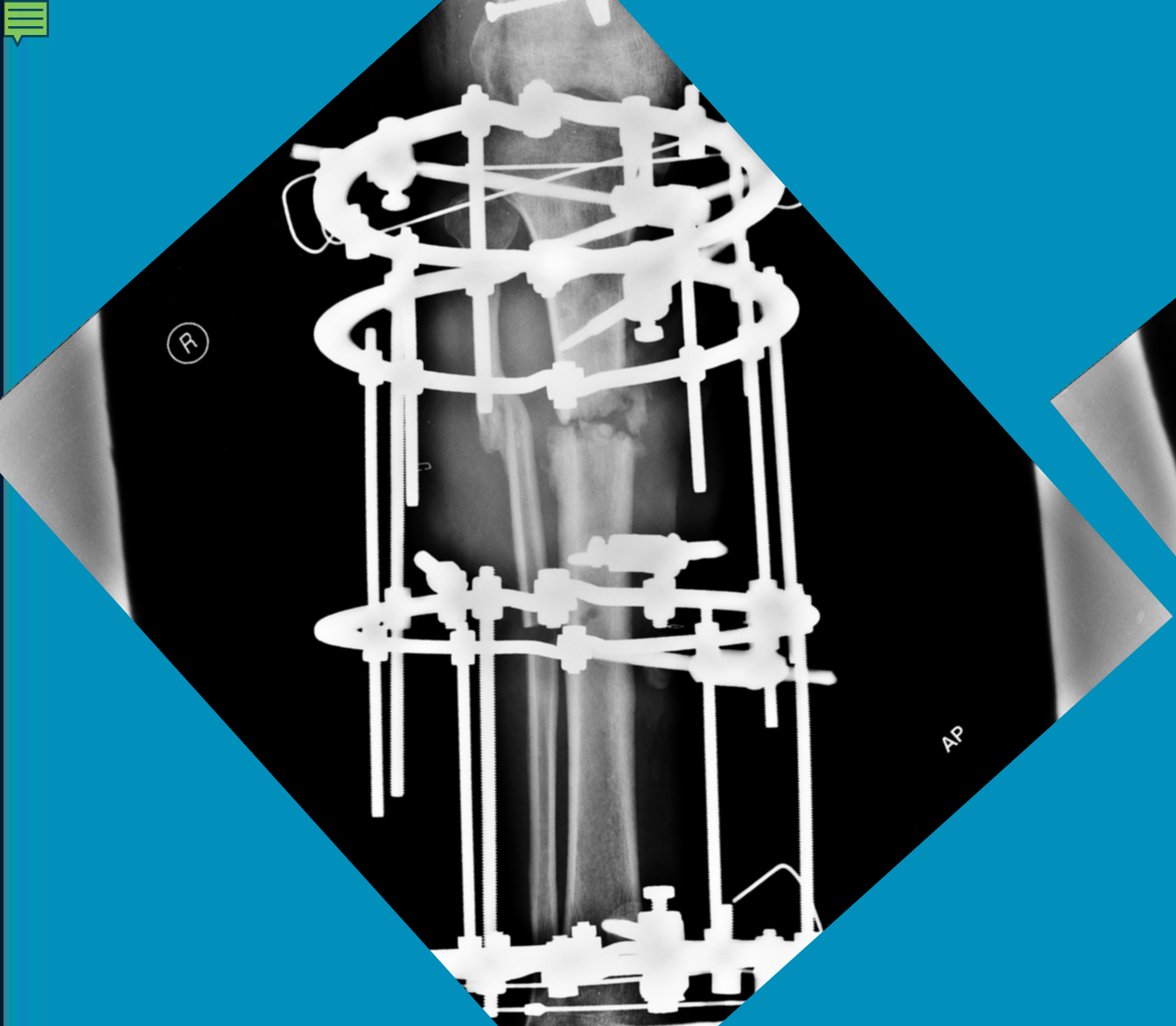


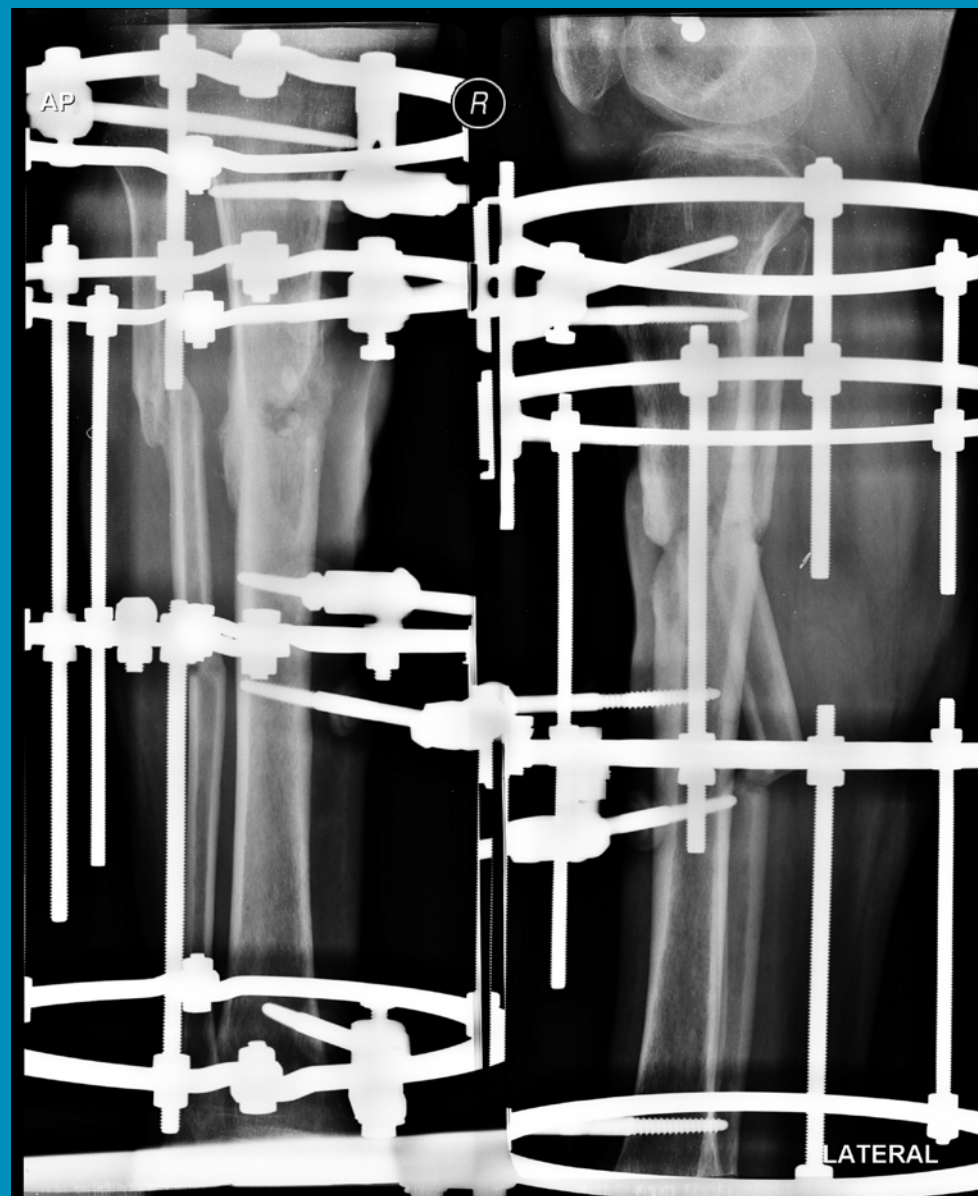Devidas suffered polytrauma in the line of duty as a policeman with a compound fracture tibia and comminuted femur on same side. While femur was fixed with a nail, the tibia was inadequately fixed with an exfix. He had infection with a wound over the fracture surfaces. He had not walked for more than 6 months and was depressed.



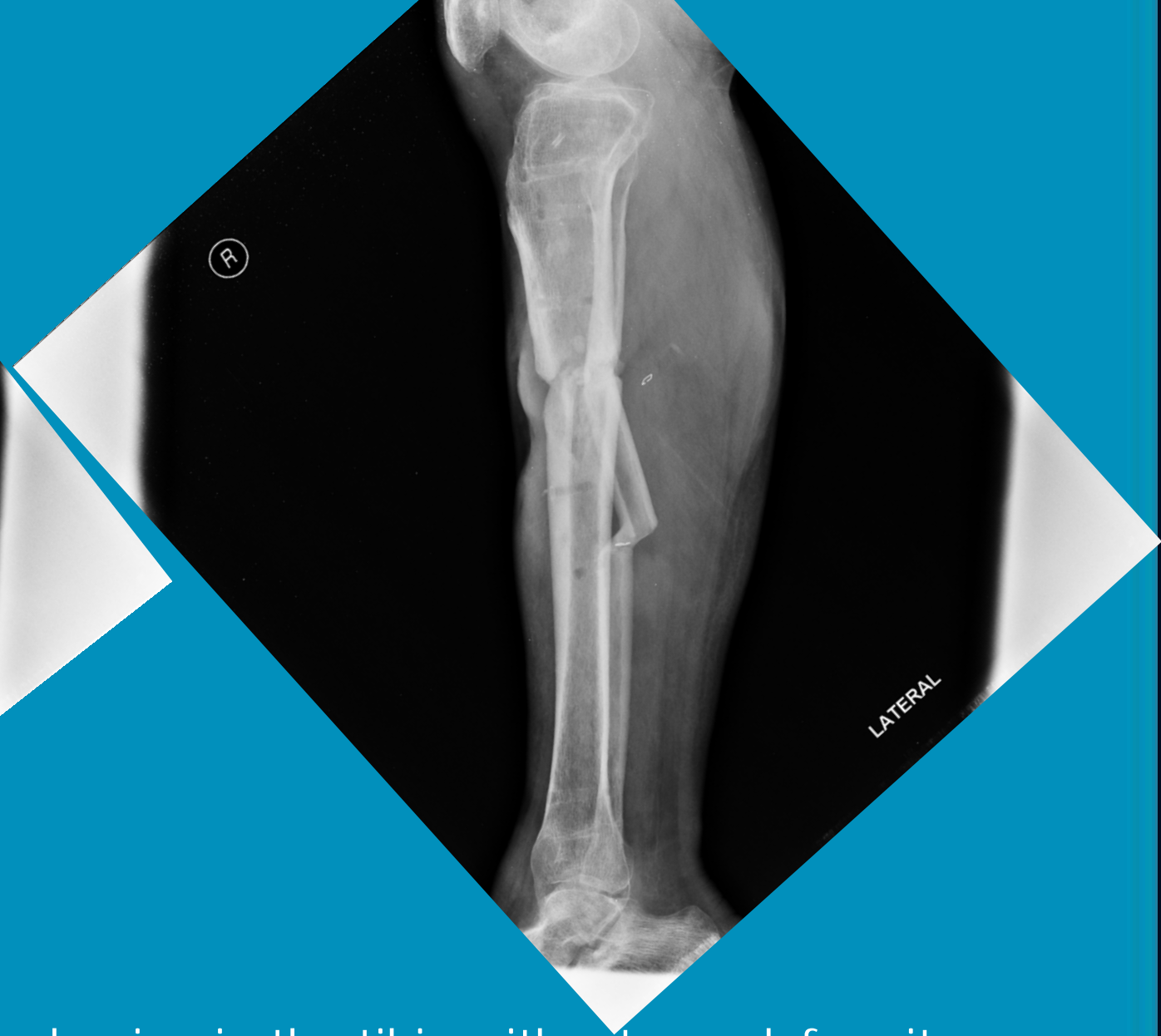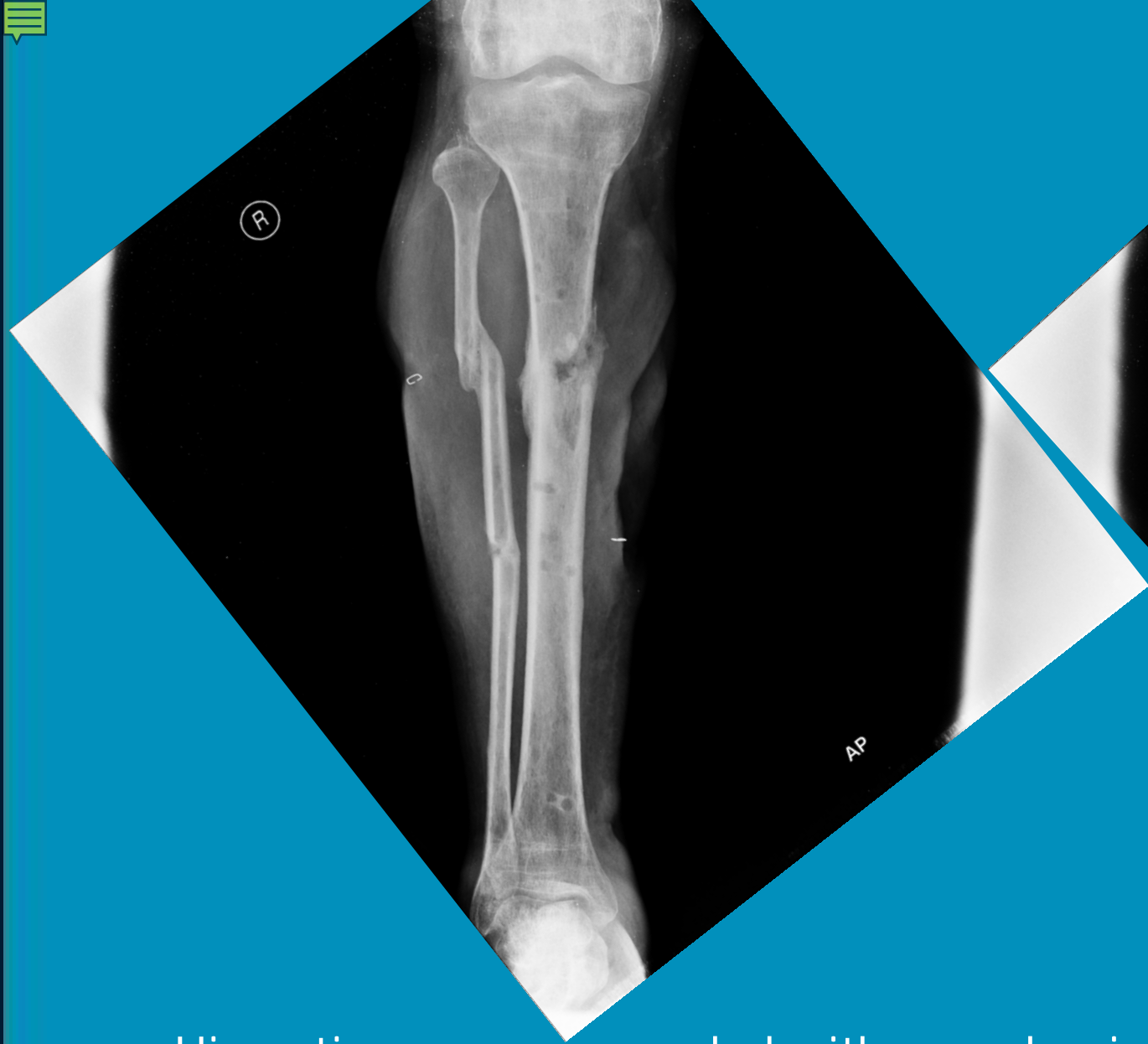Instead of relying on antibiotics to heal the infection (which was being done since the beginning) we chose to do a thorough debridement, reaming and inserted an Vancomycin impregnated cement rod to cure the infection.



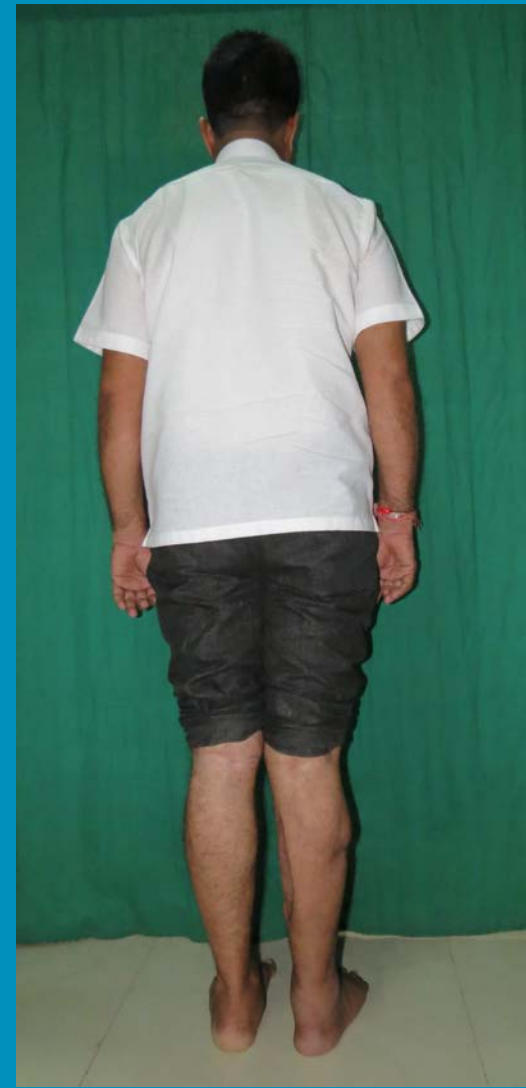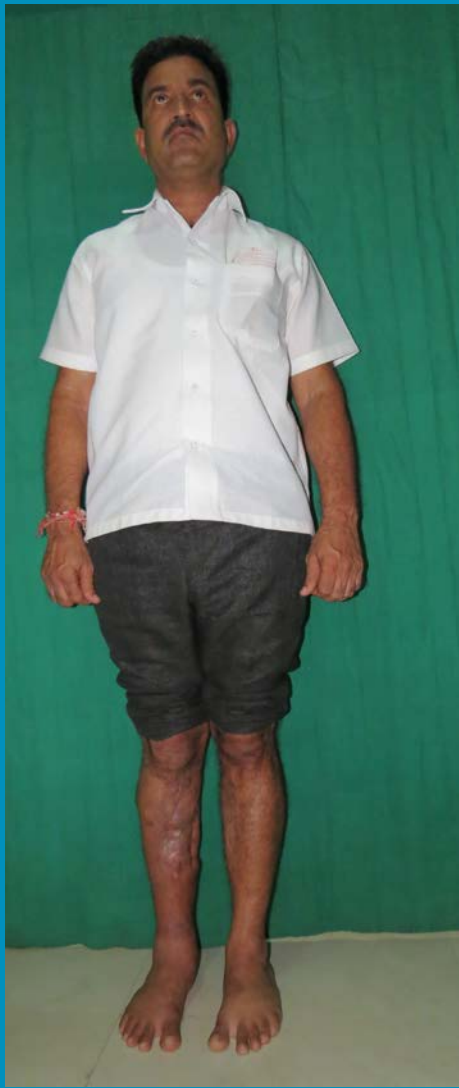In the second stage a π osteotomy was done along with the ilizarov π which gave sustained compression. Since his femur non-union did not allow him to walk we chose not to resect more of his bone though the fracture surfaces were irregular. In such situations we choose to compress minimally : no more than 1 mm in 14 days.



He could only be partially weight bearing due to tenuous union in femur nailing of a midshaft comminuted fracture. We added some bone marrow aspirate to his tibia as well as femur on a few occasions to expedite healing.



His patience was rewarded with sound union in the tibia without any deformity, infection or shortening.



He has resumed his duties as a cop and regained some of his chutzpah and composure as a tough law enforcer!