

Limb Lengthening

Introduction

The ability of chameleons to regrow appendages and limbs has spurred scientists to try to grow and lengthen limbs in man. Limbs shorten due to trauma, birth defects, osteomyelitis, tumours, and Polio. Limb shortening afflicts as much as 10% of the human population. Till the end of the 20th century, medical science was under the impression that specialized tissue like muscle, nerve and bone could not regenerate, leave alone lengthen. Recent advances in Limb Lengthening now allow lengthening of a short limb by 2 to 10 inches in one stage & also permit lengthening of limbs to increase height in dwarfs. The use of sophisticated internal and external devices and a clear insight into the biology of regeneration of tissues has made Limb Lengthening a reliable and safe surgical procedure.

History

Lengthening of a short limb has fascinated surgeons since antiquity. The earliest reports of surgical limb lengthening were by Codivilla in 1905. Limb lengthening has since been attempted by many surgeons with ingenious hardware. However all of these methods have been experimental and have mainly focused on mechanical distraction, ignoring the biology of bone.

Anderson and Wagner's methods were famous in the 1940's through 60's. Wagner's method was considered the Gold standard in the west despite the fact that it was crude and needed at least 3 invasive surgeries for achieving as less as 3 cm of length. The technique consisted of applying an external fixator with half-pins and performing an osteotomy of the bone with a large open incision. This osteotomy was distracted apart for 5 to 10 mm on the table and then lengthening with the device proceeded at 2 to 4 mm per day till the soft tissues could bear the stretch. At the second surgery, a plate bridged the gap in the bone and Iliac crest bone grafts were inserted with the hope of filling up the gap. A third surgery was frequently done to remove the plate. During most of this period, the patient was bed-ridden and unable to walk. Complications were rife and averaged at least six major complications in each case.



Dr. Milind Chaudhary with Prof. Ilizarov in 1988

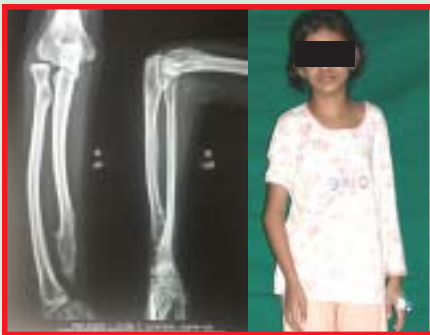Hypertension due to stretching of the blood vessels was common. Pin track infections, malunion of the bone gap and NonUnion were very common. Nerve palsies, Joint stiffness, subluxation and dislocation were all too frequent. In fact, so unreliable was the procedure that most surgeons were reluctant to advocate surgery and most patients were given a shoe raise.

Those with significant shortening were often advised surgery for shortening the opposite limb. Before skeletal maturity, stapling and epiphysiodesis to curb growth in the longer limb was routinely preferred over lengthening the short limb. Various charts and graphs were plotted after reviewing patient at yearly intervals to decide the best time for epiphysiodesis. Not only did this result in reducing the final height of the individual, but it frequently was unreliable and would fail altogether or create angular deformities in the normal limb.

Even as the Wagner method and Epiphysiodesis were ruling the roost in the western hemisphere in the sixties through eighties, an unknown (to the west) Soviet physician in the remote wilderness of Siberia had already made tremendous strides and had firmly established the biological principles which would make regeneration of bone a reliable, reproducible and routine surgical procedure.

G.A. Ilizarov

Gavriil Abramovich Ilizarov was a General Practitioner by training practicing in the western Siberian industrial town of Kurgan in the 1940's when he began to treat increasing numbers of veterans of the Second World War with chronic limb injuries.



Shortening of the ulna due to exostosis causes protrusion & dislocation of the Radius with loss of movements and shortening of the forearm.

He devised a simple external fixator made from thin wires and various brackets, easily available from industrial supplies to treat mal-united and infected fractures. When one of his patients turned the connecting struts the wrong way, Dr. Ilizarov discovered that instead of the bone ends coming in firm contact, they had separated and surprisingly, soft bone had formed between them. This set him on the path of discovery of the principles of Limb lengthening—a science which has helped thousands of people all over the world. He earned his Ph.D and nomination to the prestigious Soviet Academy of Sciences by elaborating on the principles of lengthening. By 1970, Dr Ilizarov was a Soviet National hero and presided over the largest orthopaedic hospital in the world with 18 departments, 300 physicians and researchers, and at least indoor 1000 patients all being treated by his methods.

He set about traveling around the world in the late 1980's and came to Mumbai in Oct 1986 where he enthralled the entire audience with his amazing achievements.

His methods first spread to Italy in the 1980's where a young American surgeon, Dror Paley trained and started Limb Lengthening surgery in USA in 1987. This author has had the privilege of being the first surgeon from India to do a Fellowship with him in USA and also to train in Prof. Ilizarov's institute in Russia. Since then more than 900 limb lengthening surgeries have been performed in India successfully at the Centre for Ilizarov Techniques at Akola and at Jaslok Hospital. .

Causes of Limb Shortening

Estimates of the incidence of limb shortening tell us that as much as 10% of the human population has limb length inequality to the extent of 1 cm or ½ inch. A study by Kawamura found leg length discrepancy of more than 5 mm in 30% of healthy athletes.

Congenital anomalies (Birth defects) with limb reduction deficiencies like Radial Hemimelia, Ulnar Hemimelia, Congenital Short Femur (Proximal Focal Femoral Deficiency) Fibular Hemimelia, Tibial Hemimelia, are the commonest causes of one side limb shortening.

Severe forms of these cause the most severe amounts of shortening exceeding 15 to 20 cm by skeletal maturity.

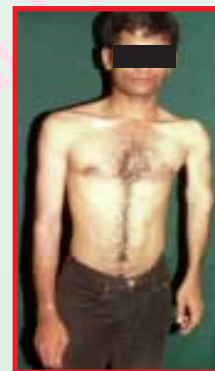Complex deformities with severe shortening cause significant disability & difficulties in bracing or Orthotic fitting. Though children adapt easily to shortening and deformities, the onset of adulthood brings early arthritis and pain.

Road Traffic accidents and Trauma accounts for a large number of mal-united fractures with shortening. Mild Shortening (upto 3 cm) is frequently found with Malunions in Tibial fractures treated with plaster casting or Functional Cast Bracing. Moderate shortening is seen in people who suffer from Polytrauma—or multiple fractures. Infection following fractures leads to resorption—dissolution—of bone. With sequestration—death of bone—more bone mass is lost and shortening results along with a gap in the fracture. This is frequently accompanied by joint stiffness, infection and deformities.

Many childhood fractures of the femur end up with unacceptable residual shortening. Growth arrest due to Physeal (the “growth plate” seen at the end of long bones, which is responsible for increase of length)injuries accounts for significant shortening along with deformities. It needs a very careful evaluation with repeated measurements of length discrepancy to determine the true extent of shortening at maturity.

Osteomyelitis is commonest in the metaphyseal region (flared ends) of long bones from where it invades and damages the physis or Growth Plate. Dramatic shortening exceeding 20 to 25 cm can occur when the lower femoral physis is damaged. Partial physeal arrest can cause large and grotesque deformities as well—those exceeding 90 or even 180° with rotation and angulation along with shortening.

Neurological conditions like Cerebral Palsy may cause a small amount of true bony shortening. Joint contractures and deformities can mimic shortening, but true shortening rarely exceeds 3 to 4 cm.



10 cm shortening of humerus due to childhood osteomyelitis



Severe 180° deformity with bone gap & shortening due to osteomyelitis.

Residual paralytic Poliomyelitis, though not commonly seen de novo, is present in very large numbers in India. Lower limb shortening is a common accompaniment of muscle paralysis. Joint contractures and instability along with weak muscles tend to amplify the effects of even small amounts of shortening. 2 cm of shortening can result in arthritis of several joints in the affected as well as the normal limb by age of 35 years in Polio. Shortening of 5 to 7 cm is common making the leg dangle. Absolute equalization of limb lengths is frequently not necessary and a mild residual shortening (1 to 2 cm) is beneficial as muscles needed to clear the floor may be paralysed. If limb lengths are equalized, energy consumption of gait may increase.

Excision (surgical removal) of benign and locally aggressive tumors creates bony gaps and shortening which need to be filled up and corrected. Dysplasias (malformation) and destruction of the hip joint are accompanied by 3 to 10 cm of shortening. The mechanics of the hip joint need correction along with the correction of the shortening.

Effects of Limb Inequality

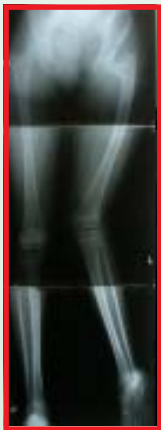Shortening of the upper limb may create no significant problems. The difference is not noticeable till it exceeds 15%. Mild to moderate amounts of shortening is usually not a strong indication for surgery in the arm. However, in the forearm; mild shortening of Radius or Ulna is an absolute indication for lengthening as they can disrupt the proximal and distal Radio-Ulnar Joints. This leads to a loss of movements of the forearm--necessary for such activities like tightening of screws, receiving "prasad" etc. Large amount of shortening of the humerus can lead to a lack of reach, especially when combined with a contracture of the elbow joint. Riding a two-wheeler can become difficult.

The tolerance for shortening in Lower limbs is much lesser. Small amounts of limb length difference can create excessive energy demands on walking. Excessive forces on the joints while weight bearing can predispose to arthritic changes in neighbouring joints as well as lead to early backache. Wearing a shoe raise could be acceptable for a discrepancy of about 2 to 2.5 cm. A larger shoe raise can become heavy and predispose to falls while walking. Limb lengthening is now a safe and routine surgery and should not be denied to patients.

Evaluation of Limb Discrepancy

Clinical

Clinical estimation of limb length discrepancy is prone to error--especially when the difference is small. An approximate idea of the amount and location of shortening is possible using simple clinical tests. The level of the ASIS (prominence on pelvis on which the trousers rest) while standing gives a rough idea about amount of shortening. The Galeazzi test with the patient lying supine (on the back) gives an idea of the location and amount of shortening. The same test with patient lying prone gives a much clearer picture--as to how much shortening arises from the thigh and how much from the leg bone.

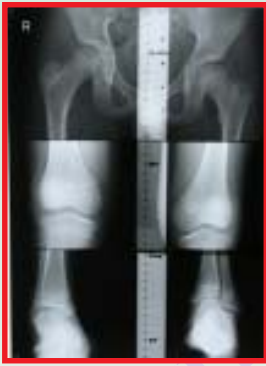

Full Length xray taken with special long cassette showing shortening & deformities.

True Shortening may arise from the pelvis, femur, tibia or the foot. Apparent shortening may be caused by scoliosis (curvature) of the lumbar spine, or due to a pelvic tilt caused by a hip abduction contracture on the opposite side. Apparent shortening is also seen in Fixed flexion deformities of the knee.

A thorough clinical examination of the joints with Range of Motion, Contractures and Deformities is noted. Instability of the joints should be diligently looked for. A telescoping test of the hip as seen in a destroyed femoral head will warn about the dangers of performing femoral lengthening.

Testing for Antero-posterior (front to back) stability of the knee is important when doing Femoral lengthening. Posterior subluxation of the tibia can occur with lengthening in congenital cases. A Ball and Socket ankle as happens in Fibular Hemimelia can cause subluxation of the ankle.



Scanogram taken in one film with three exposures of the hip, knee and ankle showing shortening.

Radiological

Estimation of true shortening is best taken with a **full length xray**. Extra Long cassettes measuring 14" x 51" (for adults) & 12" x 36" (for children) are used. The patient is standing and care is taken to keep patellae (knee caps) pointing forwards. Wooden blocks are kept under the short leg till the pelvis is squared. The cassette contains three screens and three individual films of 14" x 17" or 12" x 12" are inserted. A single exposure is made from at least 7 feet away with the focus on the knee. The legs are kept parallel to the film.

The cassette extends below the foot so that foot height can also be estimated.

This film gives a true estimate of shortening as well as condition of the various joints.

Scanogram

When a long cassette is not available, a single 14" x 17" cassette can be used with a Bucky to take three separate exposures of the hips, knees and ankles (also including the pelvis and the foot) with lead separators. The limb position is not moved between the exposures. A calibrated perforated metal scale is kept on the Xray table. This helps get a read-out of the shortening at individual segments.

CT Scanogram is a very accurate method of as long as the measurements are taken accurately or as long as the scale of the film is mentioned.

Stages of Limb Lengthening

Limb Lengthening has three phases.

- Latency—varies from 5 to 10 days after surgery, depending on type and gentleness of osteotomy. This allows the fracture healing mechanisms to start.*
- Distraction—lengthening is done at 1 mm per day till desired length is achieved.*
- Hardening—the soft bone that forms now hardens and a cortical tube is allowed to form. This phase may take as much as twice as long as the distraction phase.*

Biology of Limb Lengthening

The Law of Tension Stress was elucidated by Prof. Ilizarov as a general biological law. It states that when living tissues are subjected to graduated planar distraction forces in the presence of intact function and vascularity, and the bone is subjected to a low energy osteotomy, new bone and all other tissues in the limb are formed by a process of NeoHistogenesis.

Prof Ilizarov conducted a series of landmark animal experiments, which clearly proved the mechanism of new bone tissue formation and the factors necessary for its proper formation and maturation.

The necessary ingredients for successful lengthening are:

Stability of fixation

Stable fixation can be achieved by having more pins or wires. In case of wires, they must be adequately tensioned to between 90kg to 130 kg/mm²

The angular spread and distance between the wires should be maximized to increase stability. Ideally the wires must be spread 90 degrees apart either in the same ring or between a block of rings. Whenever possible each fragment should be fixed with two rings to increase the distance spanned by the wires. There should be more connections and they should be kept tight. If the connections grow loose, then the bone formation can "disappear".

Atraumatic corticotomy

The corticotomy should be as close to the metaphysis as possible. It should be a low energy osteotomy with as less damage to the periosteum as possible. The classical corticotomy is made with a 5 mm incision. In the tibia, an osteotome is inserted from the antero-lateral corner and only cuts the anteromedial cortex and the lateral cortex. The posterior cortex is

only breached at the postero-medial and postero-lateral corners. The remaining posterior cortex should be breached by a rotational osteoclasts manouvre.

In the femur, the osteotome is inserted from lateral surface and cuts the anterior and posterior cortex. The medial cortex is breached by rotational osteoclasts.

In the Drill Hole corticotomy as well, the drilling should be done in the pulse mode along with cool saline lubrication to dissipate the heat. Care must be taken to preserve the periosteum during drilling as well as osteotomy.

In the Gigli saw variety, the wire saw must be passed sub-periosteally by gently elevating the periosteum with a thin elevator. In the tibia, two small incisions are made, one antero-laterally and another postero-medially. The periosteum of the lateral and posterior cortex is gently elevated. A hemostat carrying a thick thread is introduced from the antero-lateral side. An empty hemostat is inserted from the postero-medial and tries to gri the thread and pulls it out from postero-medial corner. The Gigli wire saw is now brought in behind the thread from lateral to medial. This wire saw cuts the lateral and posterior cortices and then as it cuts the antero-medial cortex, care is taken to ensure it does not violate the periosteum on the antero-medial aspect. The gap created by the saw is compressed.

In any variety of corticotomy, there should be no initial gap in the bone or any displacement of the bone fragments. If present, all attempts must be made on the table itself to ensure that it is rectified. The operative technique must be gentle.

Gradual Rate and Rhythm of Distraction

The amount of distraction done in each step must be as small as possible. Practically in the manual mode, this should be about $\frac{1}{4}$ mm at a time; not exceeding one mm in a day. This is easily done by the patient with the help of spanners in the Ilizarov or an Allen key in the Orthofix system. The TSF system has knurled knobs on the graduated distraction rods to enable easily doing it by hand. Ideally even smaller amounts of distraction are better and an automated distractor would be able to achieve 1 mm of distraction broken down over 60 steps. This decrease of the rate and increase in the rhythm yields better and more homogeneous bone formation.

If bone formation is poor, the rate should be lowered to $\frac{1}{4}$ mm twice a day. If the bone formation is hypertrophic it should be increased to $\frac{1}{2}$ mm thrice a day for a few days. By increasing the rate and reducing the rhythm, bone formation slows down.

Retained Joint and Limb function

Allowing the patient to walk around and function preserves and promotes circulation to the limb. This is crucial for new bone formation. In children below 10 years of age, supervised walking or activities are not necessary as bone will form anyway. In adults in all lower limb lengthening, isometric exercises and walking are crucial to bone formation. The amount of walking and exercises has to be more than 5 to 6 hours a day. In experiments it has been proved that amount of blood flow to the limb increases by $2\frac{1}{2}$ times towards the end of the distraction-lengthening-phase. Smoking hampers blood flow and new bone formation and we are completely reluctant to operate on anyone who smokes.

Methods of Lengthening

A-External Fixation

The Ilizarov fixator.

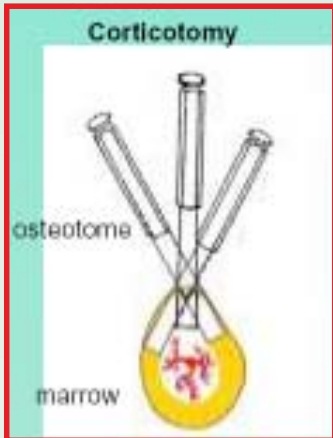
This is a thin wire circular external fixator with many modular components. This allows fixation of all small and long bone segments. The classical Ilizarov fixator uses 1.8 mm wires which are tensioned with a calibrated tensioner to 130kg/mm²

These are attached to the rings which are made of steel or carbon fibre. Hinges and other modular parts allow correction of deformities as well. Threaded rods help distract rings apart for lengthening or correction of angular, rotational and translational deformities.

Types of Corticotomy

After bony fragments are fixed with rings the bone is divided with a low energy osteotomy using a 5 mm osteotome. Care is taken that the osteotomy is not traumatic and that it is undisplaced. This is performed in the metaphyseal zone where wider bone can form.

This method of corticotomy works well in the presence of an all wire fixator. When hybrid fixation is used and half pins inserted near the corticotomy site, the corticotomy can break into one of the pin holes. Hence drill holes are made with 3.2 mm twist drills and the osteotomy is completed.



Another method is the Gigli saw osteotomy. Two small incisions are taken and a thin thread is passed around the tibia. The Gigli wire saw is attached and pulled around and the osteotomy completed with two small incisions. The advantage of this method is that the connections do not have to be dismantled prior to corticotomy as in the other methods and that it is invariably complete. In the other two methods there is a chance that parts of the posterior cortex may not be cut completely, especially in children.

The Gigli wire saw and the drill hole osteotomy needs a slightly longer latency period as compared to the traditional corticotomy in which 5 days of latency may be enough.

In the leg, the fibula is osteotomized at the lower level and it is fixed with a wire or a syndesmotomic screw to prevent it being pulled out of the ankle joint.

In the femur, proximal fixation is achieved in most patients with the help of a hybrid construct in which an arc allows fixation with half pins. Distally rings are used and these may be fixed to bone using either wires or pins.

The circular shape of the Ilizarov fixator has a many advantages. It is a stable construct and allows accurate and complete 3-Dimensional correction of bony deformities. On the flip side, the fixator may be cumbersome to wear in the femur and needs a lot of special nursing care like having special cut out mattresses to accommodate the bulk of the rings without causing malposition of the joints. These are minor inconveniences and can be borne easily.

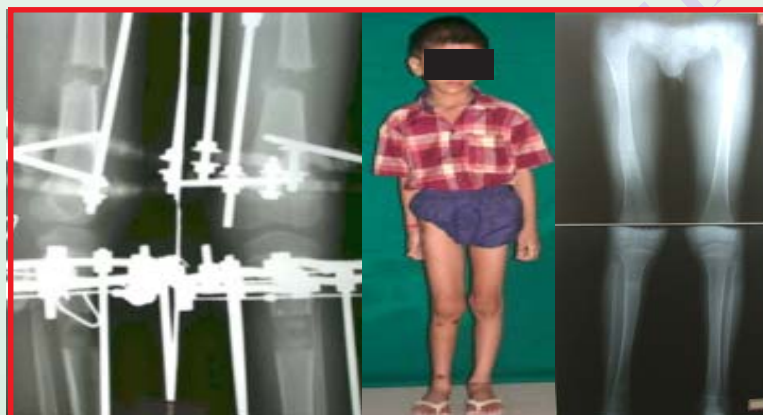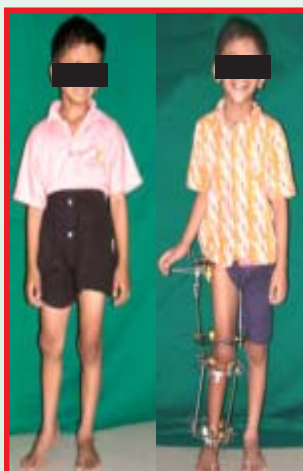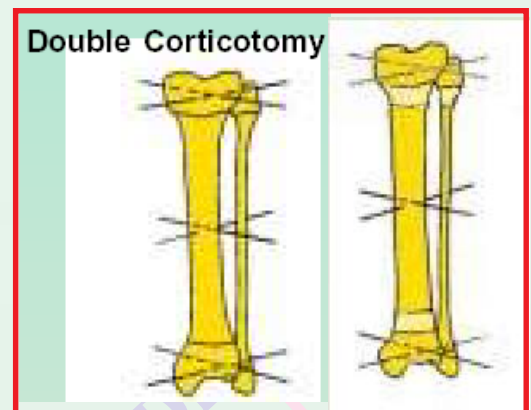
Pre-Operative Planning

A thorough clinical examination and counseling of the patient / parents are necessary. Realistic goals of lengthening are to be mutually agreed upon.

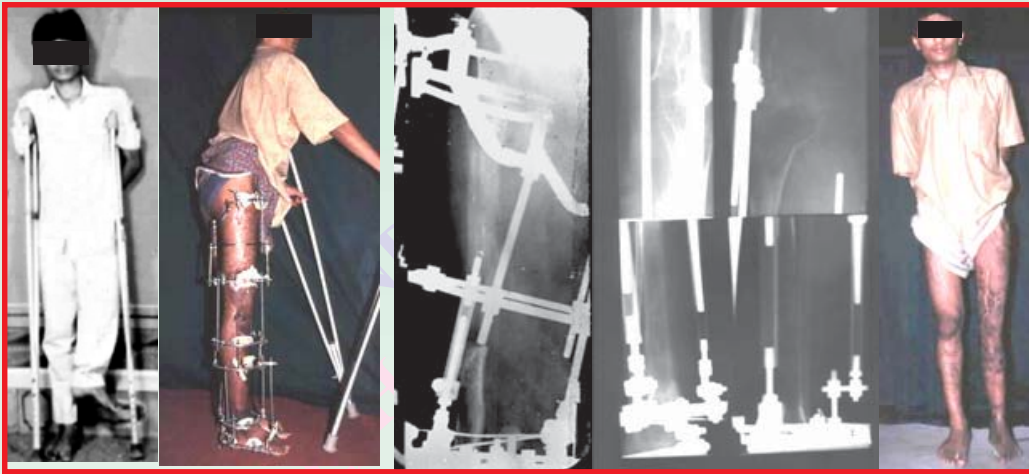
Single level lengthening is adequate for lengthening to 6 cm. Beyond 6 cm lengthening can be done as a Double level procedure in one segment. If shortening is present equally in the femur and tibia, both can be lengthened. If a small amount of shortening is present in the femur and most of the shortening is in the tibia. Lengthening may be done only in the tibia.

Double Level Lengthening

The bone is cut at 2 levels—upper and lower ends of the bone—and at each level lengthening is done at approximately 0.5 to 0.75 mm per day. This is undertaken if the desired length is more than 6 cm.. Here the total duration may be decreased by about 40%. The great benefit of this procedure is that it cuts down



10 year old child with 7 cm shortening in Femur and tibia
 high degree of comfort in fixator, good bone formation and hardening
 limb made slightly longer to compensate for future growth



same patient as in Fig 2 having 26 cm shortening in the Right lower limb due to multifocal osteomyelitis in childhood

lengthening thru 3 zones, femur, tibia and thru the zone of arthrodesis of knee

full 26 cm length achieved in one stage of treatment.

Longest external lengthening done in India.

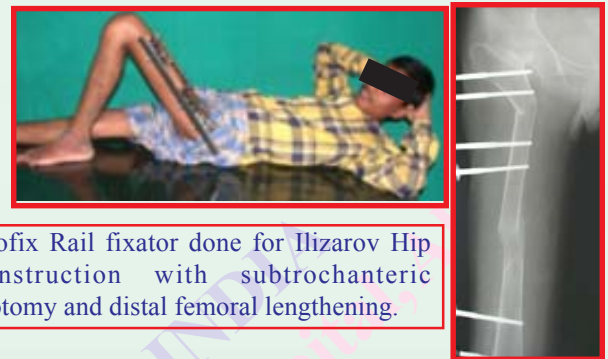on the stretch experienced by important soft tissue structures like tendons and nerves—damage to which may be the limiting factors to Lengthening. By reducing on the duration that the fixator is on the limb, stiffness of joints and other problems get minimized. Provision must also be made for deformities if any are present.

Status of joints will decide the course of action. If instability is present in the hip, a Pelvic support osteotomy can be planned. With instability in the knee, femur lengthening should be combined with a tibial frame protecting the knee with hinges. If a double level lengthening is done in the tibia, the ankle must be spanned and the foot must be included in the fixation.

Orthofix fixator

This is a monolateral fixator available in the form of a rail or a telescoping multi-joint assembly. It has good instrumentation allowing quicker assembly. It only takes 6 mm half pins passed in one plane attached to a clamp. It is axially stiff and strong. It always needs a drill hole osteotomy. It has slightly greater comfort for the patient for positioning in bed and mobilization and bending of the knee.

However, it is less versatile as compared to the Ilizarov fixator and it cannot be used at all in osteoporotic bone. The pins cannot be passed in different planes and hence it may offer less stability. Post-operative control over axial deviation with the fixator is not as easy and may need modifications under anesthesia rather than on an Outpatient basis as is done with the Ilizarov fixator.



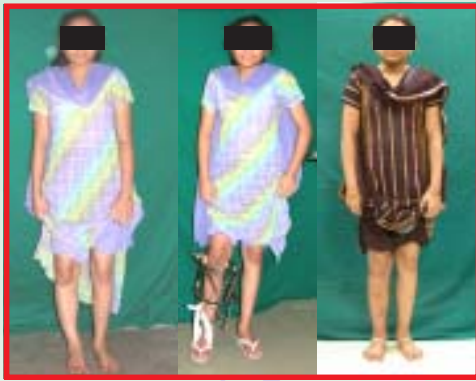Orthofix Rail fixator done for Ilizarov Hip reconstruction with subtrochanteric osteotomy and distal femoral lengthening.

Taylor's Spatial Frame Fixator

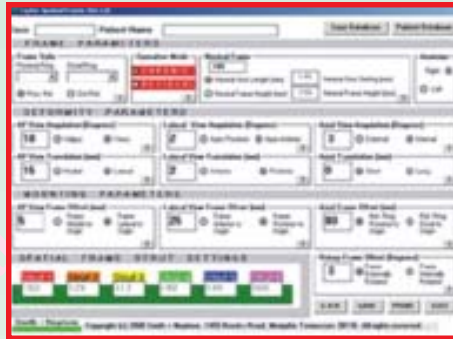This is an advanced version of the Ilizarov fixator and is made from circular aluminium rings and uses six struts instead of the 3 or 4 used in the Ilizarov. The position of bony fragments is controlled by software. 17 measurements from AP and LAT xrays are fed in the software and it allows lengthening, shortening, as well as correction of the angular rotational and translatory deformities with great accuracy.

In the words of its inventor, Dr J. Charles Taylor; the big advantage of this fixator is it dissociates the fixation from reduction or deformity correction. Its great advantage in Limb lengthening surgery is that it makes the job of post-operative alterations very easy and quick for the surgeon as there are time consuming construct changes that need to be done as in the Ilizarov fixator.

The fixator is slightly less modular and the six criss-crossing struts may come in the way of visualization of the regenerate bone. It is also slightly bulkier than the Ilizarov fixator and certainly much more expensive as it IP protected.



20 year old with shortening and deformity due to growth arrest. Under treatment with the TAYLOR's Spatial Frame fixator which is software controlled for great accuracy.



The interface of the software programme.

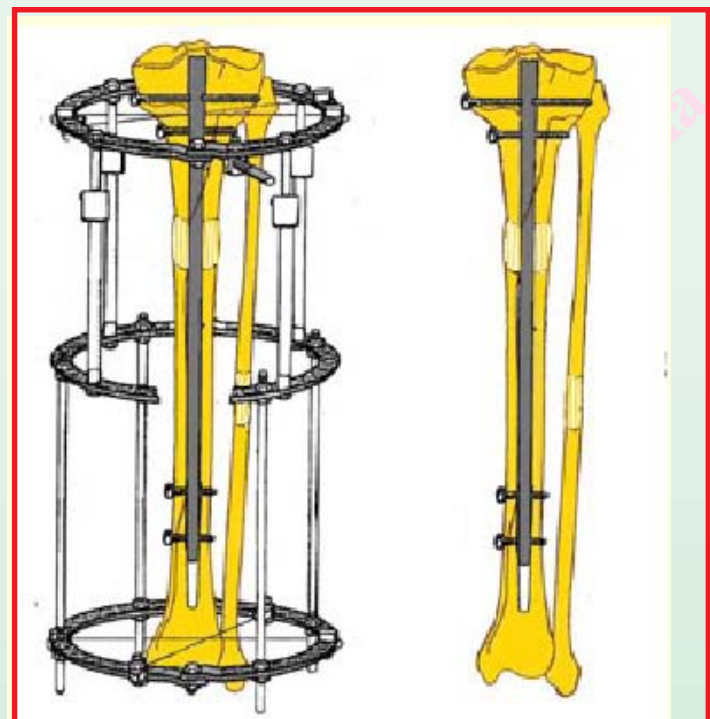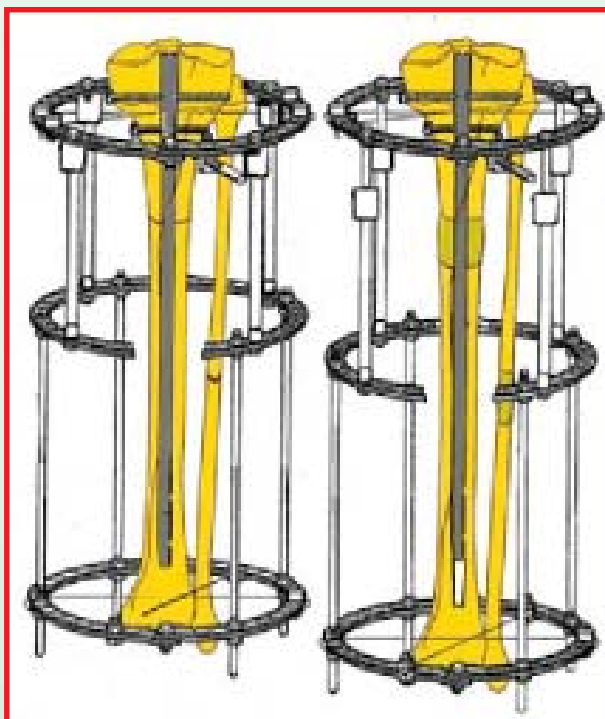


The TSF Fixator.

B-Combined Internal & External Methods of Lengthening - LON technique

The biggest problems faced by patients are the prolonged duration of the treatment. They typically have a lot of patience during the distraction phase as they can almost see lengthening. However the prolonged hardening phase leaves them restless. An attempt to reduce the duration of external fixation is made in the LON (Lengthening over Nails) technique. This was originally attempted by Bost in 1955 and revived by Paley in 1992. An IM rod is inserted in the tibia or femur after a corticotomy is made in the diaphysis. This is locked at one end. An external fixator is applied in such a way that the pins or wires do not touch or come close to the Internal device. The external device motors the distraction and as soon as the lengthening is over, the rod is locked at the other end to preserve the new length and the external device is removed.

This can significantly reduce the duration of external fixation—from 45 to 60 days per cm of length needed to less than 15 days per cm. In the femur, this has another advantage—the reduced duration of external fixation allows earlier regain of the knee ROM by removing the tethering pins earlier.



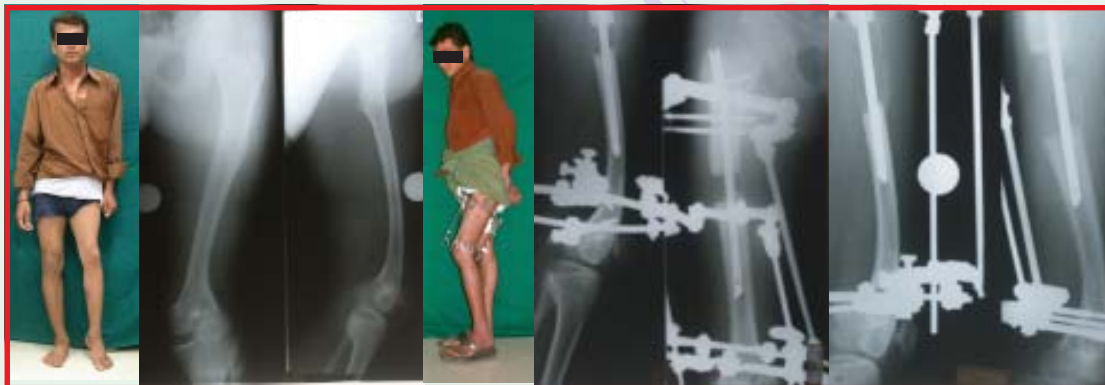As can be expected, there is a significant risk of infection due to proximity of the internal and external systems. This infection may rarely remain localized or it may spread all the way across the medullary canal. It may manifest during the treatment or it may show up much later, after removal of the apparatus.

The reaming necessary for insertion of the nail is also likely to predispose to pulmonary embolism and all care should be taken. The reaming is a necessity to allow a large nail to be inserted as well to allow it to glide easily thru the canal. A vent hole is made or the corticotomy is made before the reaming to allow the marrow contents to escape thru the corticotomy and prevent embolism.

The author has performed more than 40 lengthenings –in the femur and tibia-- with this method, over the last 12 years, ranging from 3 to 11 cm. The duration of external fixation was reduced dramatically in all cases. There were two cases of malunion and three had delayed consolidation of the regenerate. In 6 lengthenings of the tibia we chose to protect the regenerate after removal of the fixator with a above knee cast for a few months. One patient needed Iliac crest Bone Grafting to solve the problem of poor regenerate. There were no cases of any deep or superficial infection at all.

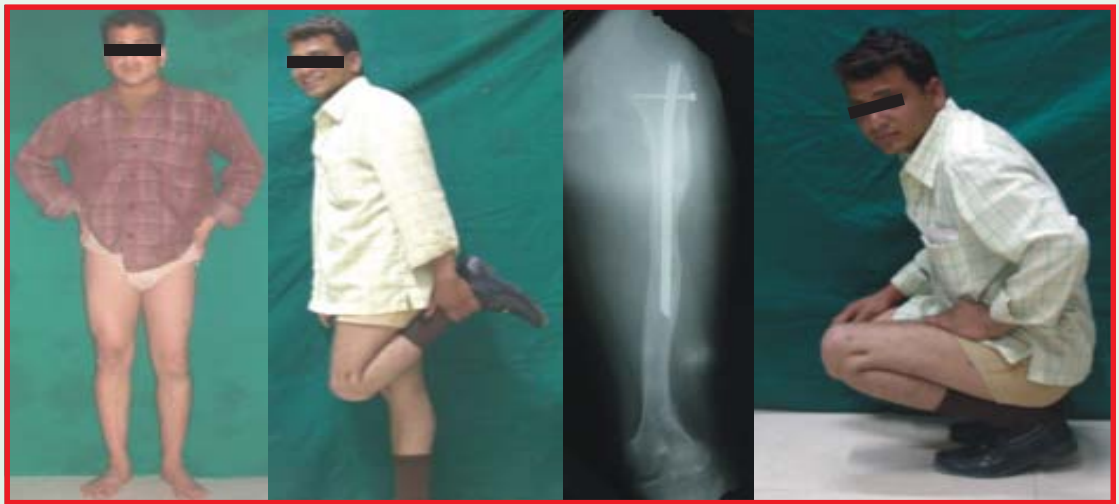When the requirement is pure lengthening with no need for deformity correction, this is a good method and can be used judiciously to enhance patient comfort.

However the potential for infection and other serious complications still drive the quest for the holy grail of limb lengthening—the Internal Bone Lengthener!



25 year old with severe shortening of the thigh bone. Lengthening performed over an Intramedullary device. The external and internal devices are not allowed to come in contact.

After length is achieved the internal device is locked and external is removed. This allows early return of Joint movements and function. This young man got 10 cm of length with the apparatus time of hardly 4 months.



C- Internal Bone Lengthening

This is the Holy Grail of Lengthening! Since the last few decades, the quest has been on for a device which will be inserted in the body and can perform safe, reliable and reversible lengthening. Such devices are now becoming available. One such has been made with a design from a French surgeon Guichet , The Albizzia nail; uses a mechanical system which creates lengthening upon rotational movement performed by the patient. It needs rotations to the extent of at least 30° to enable the lengthening.

Another made from a design based on American surgeon G Dean Cole, the ISKD device makes use of rotatory movements that occur in walking to achieve the lengthening. It uses a Neodymium (rare earth) magnet which helps keep track of the amount of lengthening. These are expensive devices and cannot be used in the presence of a significant deformity. These also do not have the ability to reverse the lengthening. The ISKD device is known to “run away” i.e. lengthen too fast; and the Albizzia device is known to jam in about 5 to 10% of cases.

The FITBONE® device was made based on the design of a German surgeon Dr Baumgart who was working on this problem since 1989. This uses a high tech programmable software controlled device that uses a battery pack to send signals to a receiver attached to the internal device. There are no mechanical movements to be done by the patient. The device is also reversible and programmable to enable slowing down or speeding up of the amount of lengthening. Lengthening of 6 to 10 cm is possible in one stage.

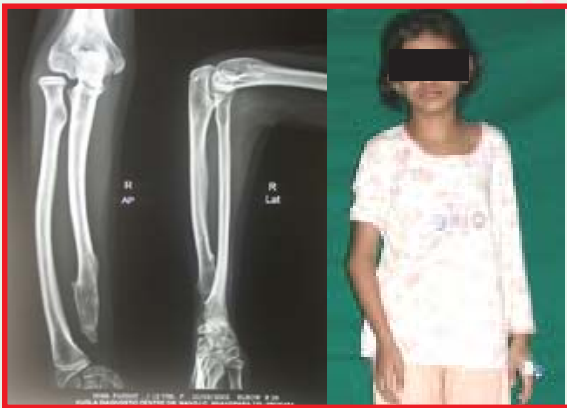Needless to say, this is a state of the art device and is expensive.

Author's Experience

Over the last 17 years more than 900 limb lengthening operations have been performed by the author. Amount of length gained has ranged from 1.5cm to 26cm in one stage. More than 550 tibial lengthenings, more than 250 femoral lengthenings and more than 100 upper limb lengthenings have been performed. Bone has formed in all except 5 cases (two being distal to an infected nonunion, two being in Congenital Pseudarthrosis and one in Osteogenesis Imperfecta). Bone grafting was needed in only 4 cases in the regenerate zone. The goals of lengthening were achieved in most patients. Less than 2% of patients fell short of their desired length. Less than 4% of cases had persistent angular deformities more than 10° at the end of lengthening. Joint stiffness developed in less than 10% of the cases. Not a single patient stopped treatment due to pain. All patients were kept mobile during the treatment.

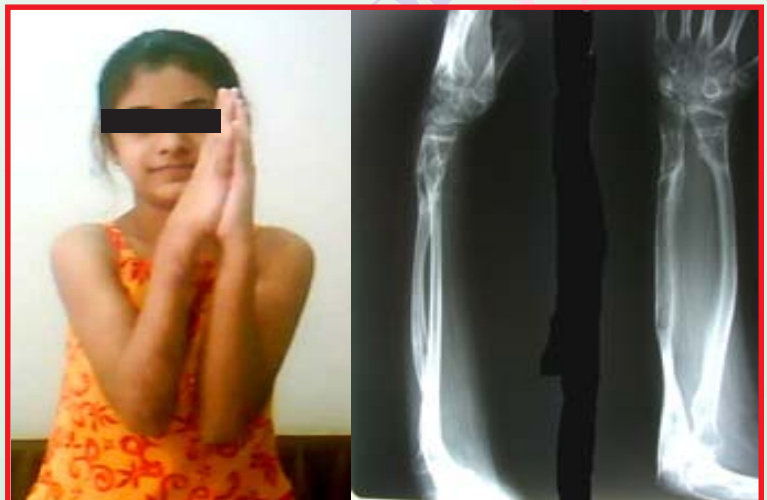The indications included the entire spectrum of Congenital, Post-Traumatic, Infective, Neoplastic, Neurological cases. Most cases of lengthening had a combination of lengthening with deformity correction or healing of a NonUnion.

Diligence till the end of treatment is rewarded with good results. Follow-up is crucial in having a control over the process. Very rarely can a surgeon hope to achieve a good result in lengthening done as an occasional case.

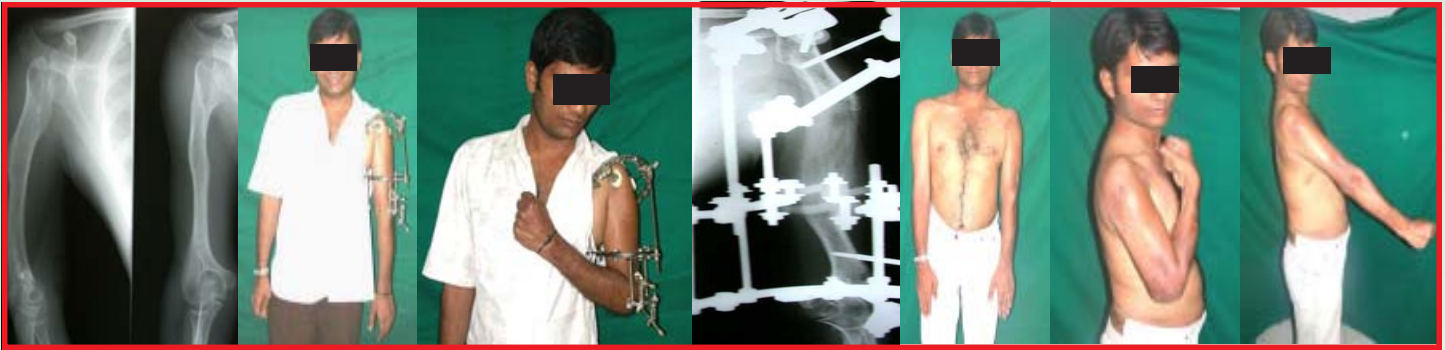

Shortening of the ulna due to exostosis causes protrusion & dislocation of the Radius with loss of movements and shortening of the forearm.

lengthening of the ulna. Note high degree of comfort during treatment.




Result with relocation of the Radius at the Prox RU joint. Xray shows that ulna has come down in the DRUJ as well.



Good ROM in the elbow and homogeneous bone formation in gap

equal limb length and full ROM



10 year old boy with 180° deformity in leg with shortening due to osteomyelitis. Lengthening to fill up gap & correction of deformity done gradually.

Complications of Limb Lengthening

Limb Lengthening is a process fraught with potential risks and complications. Most of these are preventable as well as curable with proper supervision and timely intervention. Mild ones are called *Problems*, and usually need modifications to the apparatus without anesthesia. Moderate ones are called *Obstacles* and would need some procedure under anesthesia to resolve them. Both of these types, leave no residual effects. Severe ones, called *Complications* persist towards the end of treatment, regardless of steps taken and may be considered as *True Complications*. With experience of more than 2000 Ilizarov operations, we have had our small share of the first two types but a very low rate of permanent complications.

Pain & Discomfort

For most people the amount of pain and discomfort experienced during treatment is bearable. Severe pain is rarely experienced. Discomfort is experienced initially for a few days. Inconvenience during day to day activities is more common but is not intolerable.

Pin Track Infections

This is the commonest complication and with diligence and proper adherence to technique can be kept to a minimum. Mild infections need daily dressings, moderate infections need re-tensioning of pins and oral antibiotics. Severe infections need local antibiotic injections and may need reinsertion of the pins—which may have to be done under Local or general Anesthesia. Pin Infections are the commonest cause of pain and this is usually temporary. With over 20,000 pins our rate of serious infection is less than 1%.

Problems with Bone formation

The bone formation may be slow—called Hypotrophic regenerate bone. This is due to instability or nutritional factors. It may show up late and mature very slowly. Improving stability of frame by adding rings or pins is needed. Very rarely Bone Grafting may be needed. In our experience, we have had to do only on 2 occasions out of 800 lengthenings.

Bone may form too quickly and densely—called Hypertrophic bone. This may cause the bone to heal too fast and hence stop the lengthening. This needs a re-corticotomy under anesthesia or a much faster rate of lengthening—which in turn may cause pain.

Axial Deviation

The bone may bend due to severe muscular forces. These are the commonest complications due to limb lengthening. Great diligence is needed to prevent these from occurring. A stronger frame, differential turning with application of hinges

etc. can solve this problem. This usually needs modifications to the frame without anesthesia. Sometimes addition of pins under anesthesia may be needed as well.

Tibial lengthenings have a tendency to bend into valgus and procurvatum. This is due to greater muscle bulk posteriorly and laterally. Femoral lengthenings tend to bend into varus and procurvatum. The ability to perform lengthening surgery without allowing any axial deviation is the true test of expertise---not the amount of millimeters lengthened!. Deviations may occur at any stage, including the very last stage of hardening. Typically several months have elapsed, by which time the pins have loosened and hence they allow deviations to occur. Patients are frequently in no mood to agree to another surgery however small it may be.

Nerve Problems

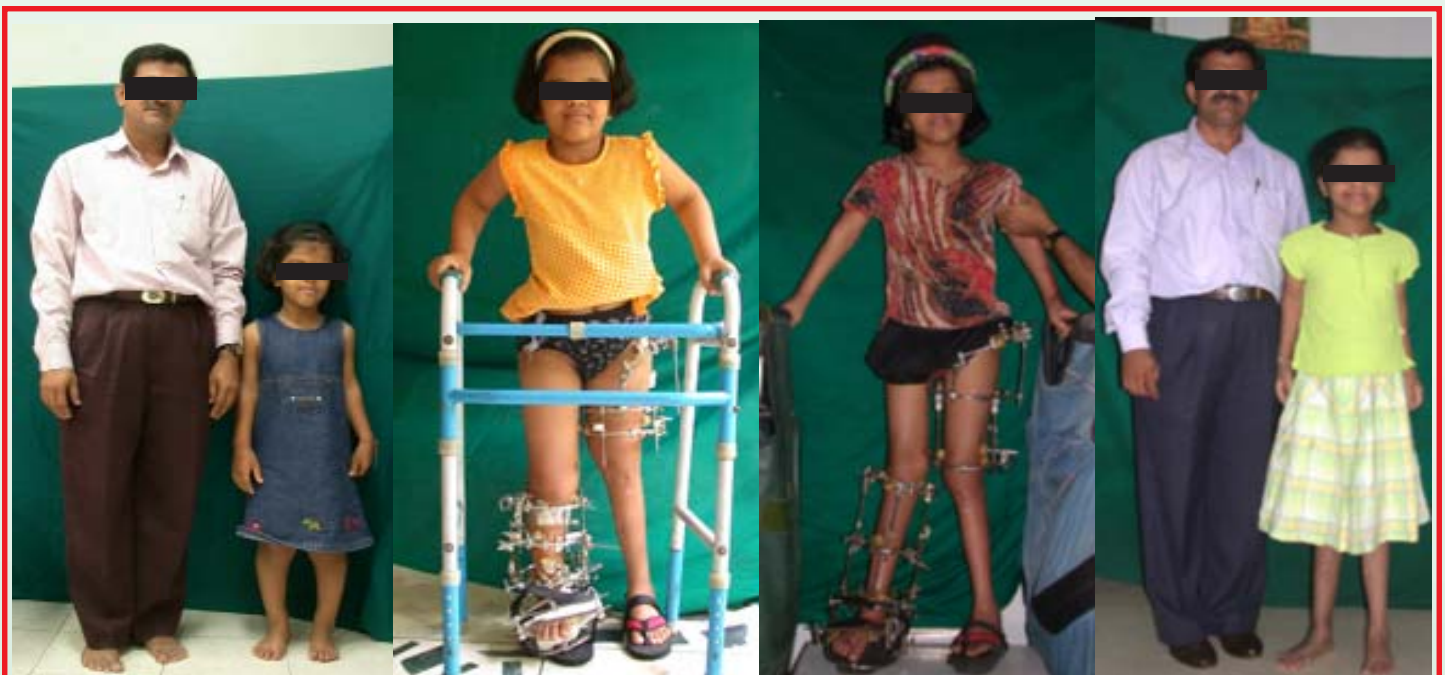Nerves may experience too much stress and stop functioning during lengthening. Daily supervision will ensure that this is caught in its earliest stages. By stopping the distraction the nerve may have a chance to completely recover. This has happened in 4 (out of 1000) of our lengthenings. Their nerves eventually completely recovered. Sometimes, the nerve may get kinked around a wire with progressive lengthening. An operation called as neurolysis may be needed to free it.

Joint Problems

The stretch experienced by the limb segment is usually translated into the joint above or below. By lengthening the tibia, the ankle joint experiences maximum pressure. If one does not stop at a modest amount, this may cause stiffness of the ankle and may cause early arthritis within 10 or 20 years. This will ensure that the joints do not seize up. Rarely the knee or ankle may subluxate or dislocate during lengthening. Extending the frame below may help relocate the joint. Congenital lengthenings need the most amount of care to ensure that joints do not dislocate or become stiff. This is because muscles are extremely abnormal, with a high fibrous content and are also much shorter than the bone.

Extensive Limb Lengthening to increase height in Dwarfs

An interesting application of limb lengthening is the ability to lengthen both lower limbs and increase the height. This has the most logical application in Achondroplastic Dwarfism. Achondroplasia is the commonest form of Rhizomelic short limbed dwarfism. It is transmitted as an Autosomal Recessive trait. Without treatment boys may be expected to grow to 4' 1" and girls to about 3' 11" only. They have typical clinical features like frontal bossing, depressed bridge of nose, incomplete extension of the elbows, trifold hands, bowing of the legs. The upper segment to lower segment ratio is skewed and instead of



10 year old Achondroplastic dwarf. Undergoing single level Femoral and Double level Tibial lengthening in a Cross Lengthening mode. Achieved 9 inches or 22.5 cm of height without complications.

the normal 1:1.1 ratio they have a 1:0.7 proportion of the upper to lower segments. They also tend to have spinal canal stenosis. While most Achondroplastic dwarfs are intelligent and well adjusted, they do tend to suffer from the social consequences of dwarfism. It may thus become a real disability for them. They also tend to suffer from early Osteoarthritis of the knee and spinal joints.

Genetics

This disease is caused by a faulty FGFR3 gene. The Fibroblastic Growth Factor Receptor 3 gene is a negative regulator of bone growth. Binding of the FGFR 3 growth factor to receptor stimulates Tyrosine Kinase activity in the cell wall and thus regulates endochondral ossification by inhibition of cell division, promotion of cell maturation and differentiation.

Mutation of the FGFR3 gene gives rise to an activation of the receptors in absence of the Growth factors causing an abnormal stoppage in bony development.

The interesting aspect of this abnormal development is that only the longitudinal development of the bone is halted. The development of muscles, nerves and all other soft tissues continues normally and hence there is redundant soft tissues available.

This makes lengthening especially easy and relatively free from complications

Our Experience of lengthening for Dwarfism

We have successfully increased the height in 42 Achondroplastic dwarfs over the last 16 years. It is possible to begin limb lengthening surgery by the age of 4 years. Lengthening is done in stages and both the femur and tibia can be lengthened. We typically begin with lengthening both the tibiae. In the second stage both femora can be lengthened. Later both humeri can be lengthened to restore proportions of the upper and lower limbs.

If the child presents at an older age, an alternate plan would be to lengthen with the cross lengthening strategy. Here one femur and the opposite tibia is lengthened in the first stage and after a suitable break, the opposite crossed pair is lengthened.

This cross lengthening is easier to tolerate as compared to bilateral femoral lengthening in older children. We can perform Double level lengthening in the tibia to achieve as much as 12 to 20 cm of length in one stage.

Great diligence and care is needed to prevent complications.

We have managed to achieve from 6 to 20 cm of height in one stage in the tibia and 7 to 10 cm in one stage in the femur. In the humerus the gain has been from 6 cm to 10 cm in one stage.

We have had mild temporary nerve palsies in 3 segments/. All of these recovered completely. 4 segments which developed a axial deviation of more than 10 degrees but less than 15 degrees. 3 ankle joints developed stiffness and lost about 25% of the movements. These were subclinical losses and did not affect the day to day activities of the patients.

Age for starting treatment

The children who started lengthening at an earlier age had significant advantages: they tended to develop an improvement in the facial features. If the first lengthening is over before the child reaches pre-school he tends to be accepted easily amongst his peers and does not develop any complexes. Though there may be issues of understanding and informed consent of the child, we have found that by age 12 or so (the recommended age of starting lengthening by western authors) the child has suffered emotionally at school by being a dwarf and the scars tend to run deep; in those who do not have enough parental support. Remember that most parents are of normal height since this is an Autosomal Recessive inheritance. Occasionally this is inherited as an Autosomal Dominant trait where either the father or mother is an achondroplastic dwarf. This is usually an easier situation to handle as the child finds acceptance of his condition easier.

