

# **Focal Dome High Tibial Osteotomy:**

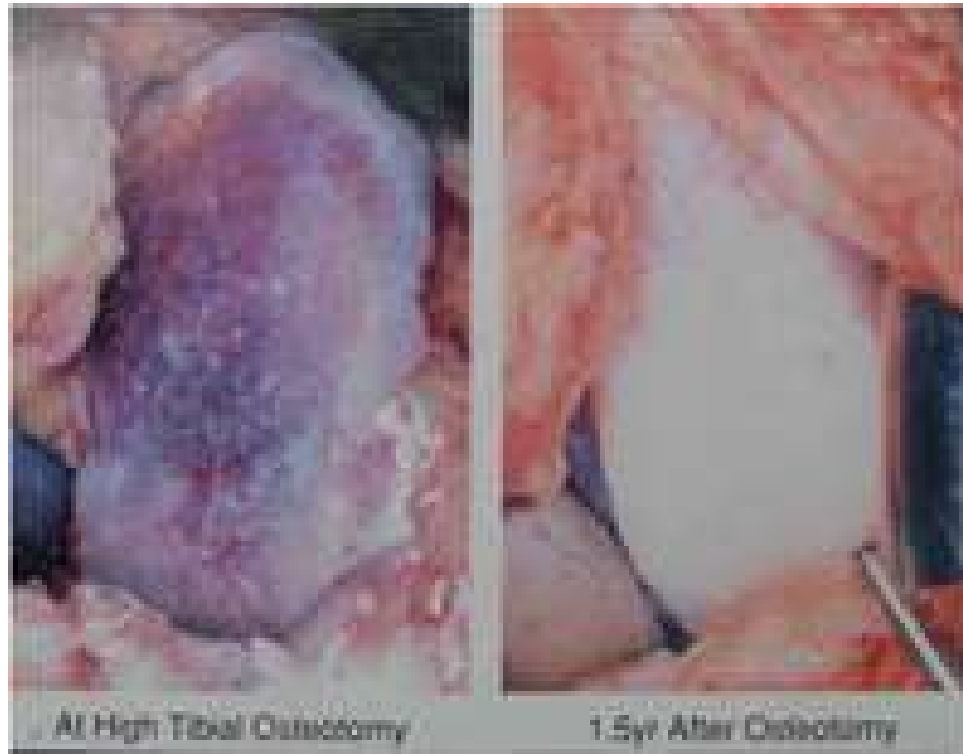**Comparison Of Alignment  
Using  
Ilizarov Fixator  
&  
Fixator Assisted Plating**

- Dr. Arunodhaya Siddartha M.S  
Clinical Fellow
- **Dr. Milind Chaudhary** M.S

Centre for Ilizarov techniques  
Akola.

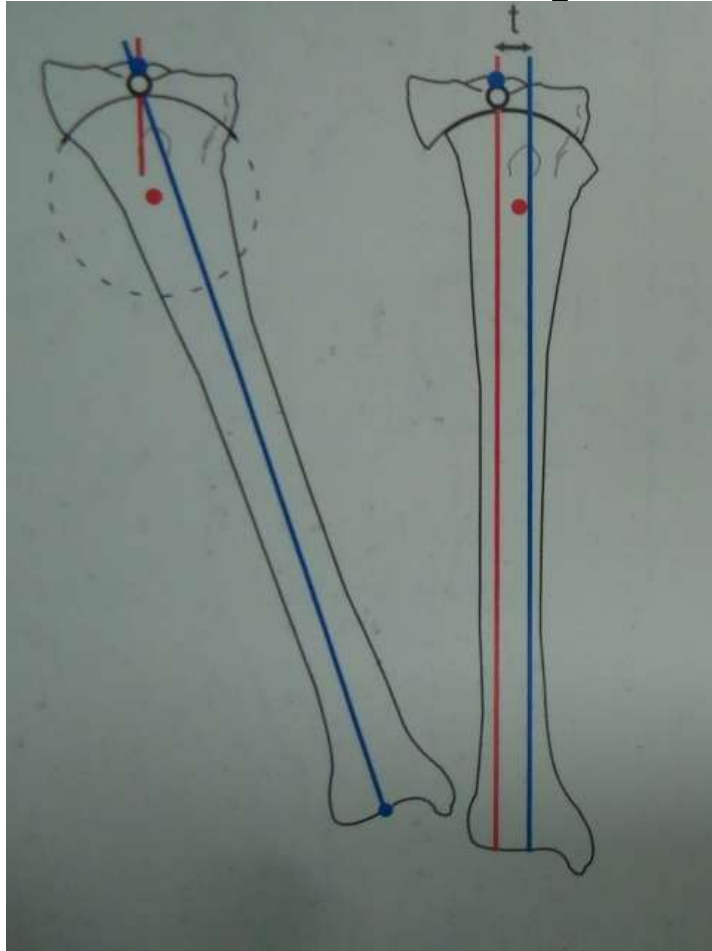
The study was conducted at our centre at Akola and included  
patients operated since 2007.

# Cartilage Regeneration after HTO

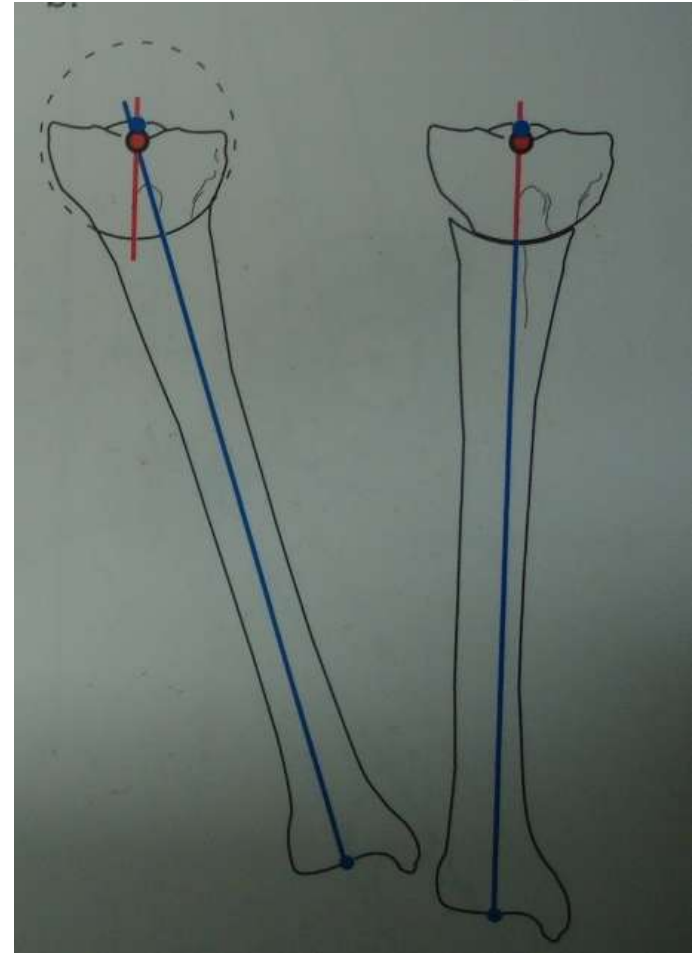


Modern High Tibial Osteotomy is a reliable treatment for Medial compartment arthritis and can help regenerate cartilage with proper unloading of the joint. The photograph on the left shows cartilage has been damaged and seen at the time of surgery. One and half years after the surgery the photograph on the right shows that the cartilage has nicely regenerated.

# Maquet Dome Osteotomy

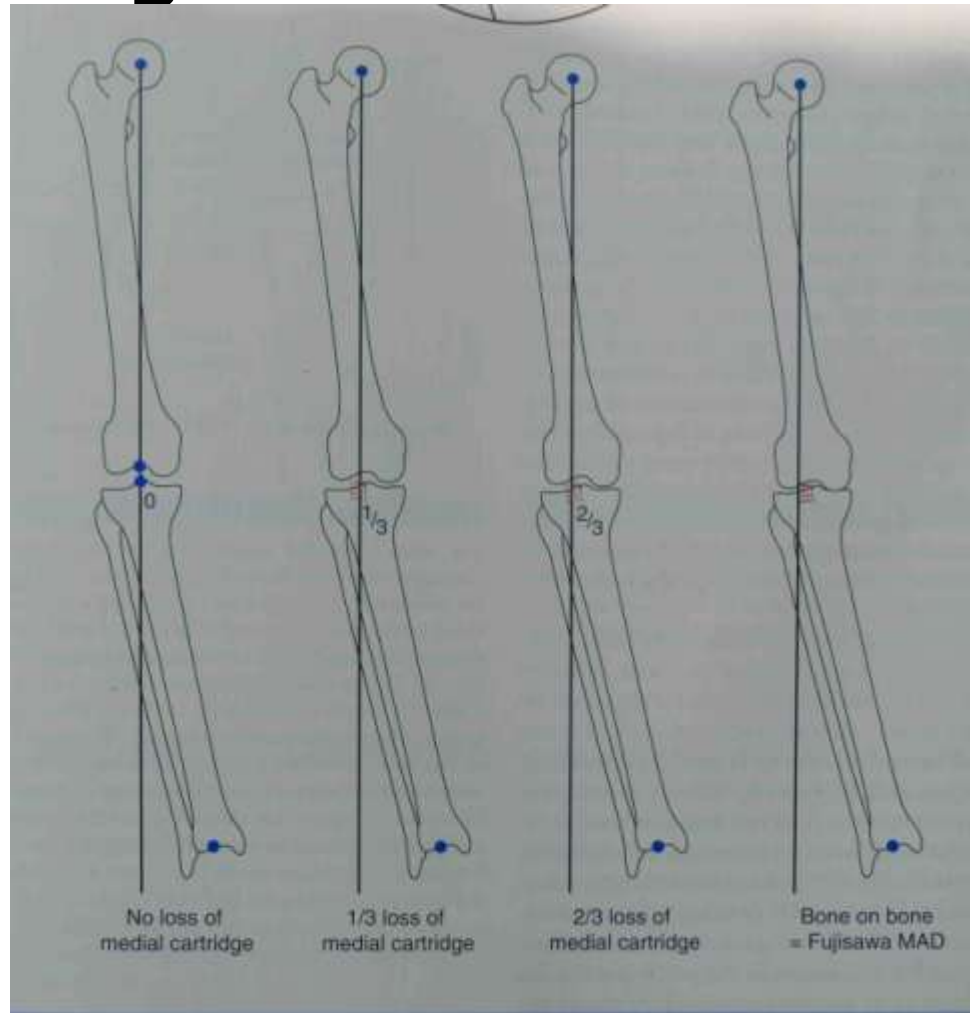


# Focal Dome Osteotomy



On the left is the Maquet Dome osteotomy made proximal to tibial tuberosity. On the right is the Focal Dome osteotomy made just distal to the Tibial tuberosity and it is based on the CORA as the hinge point. It creates an arcuate or dome shaped osteotomy with correction into valgus and minimal lateral translation with excellent bony contact. It has many advantages, namely, it unites reliably and can permit correction of large deformities

# Fujisawa Point



We aim to correct the mechanical axis to pass through lateral compartment depending upon extent of cartilage loss. The FUJISAWA point is designated past at 62% of the joint width and is considered the ideal correction. This generally corresponds to 10° of valgus correction of the femoral tibial angle.

# Focal Dome: Dr Dror Paley, 1994



Focal Dome Osteotomy was published by Dr Paley in 1994. We are performing it since 1991 and have the experience of performing no less than 250 operations with this method.

# Why Focal Dome Ost?

- No resection of bone
- Better bony contact for union
- No need for BG
- Better stability of fixation
- Larger angular correction

# Why Ilizarov

- Early mobilization
- Reliable union
- Correct Dynamic Varus
- Bilateral simultaneous
- Return to activity.
- The Ilizarov fixator is the most accurate tool for deformity correction and has all of these advantages. We have used it in more than 250 High Tibial osteotomies over 21 years. It is also minimally invasive and does not require any blood transfusions. Younger patients tolerated very well and it allows them to resume their work and professional activities is very early.



# Why Fixator Asst Plating

- Advantages of Ilizarov in accuracy
- Convenience of Locked Plating
- Early mobilization
- Full weight bearing possible
- Better in older patients & ladies.

Older patients and ladies may not be good candidates for external fixation of any sort. Hence we decided to use the same Focal Dome osteotomy , use the Ilizarov as an intra-operative alignment tool and fix it with a Lateral Tomofix Locking plate and remove the fixator.

# Comparative study

- Ilizarov .....35 ....19 Female

- FAP..... 34 ....23 Female

(using Lateral Tomofix plate)

Since 2007 we have performed the same operation, using a lateral locking plate as well. This of many advantages 4 patients will cannot come for repeated follow-ups. The absence of an external fixator enhances the comfort level of the patient dramatically. The only potential Disadvantage is the inability to correct dynamic valgus as well as the need for blood transfusion and higher antibiotics.

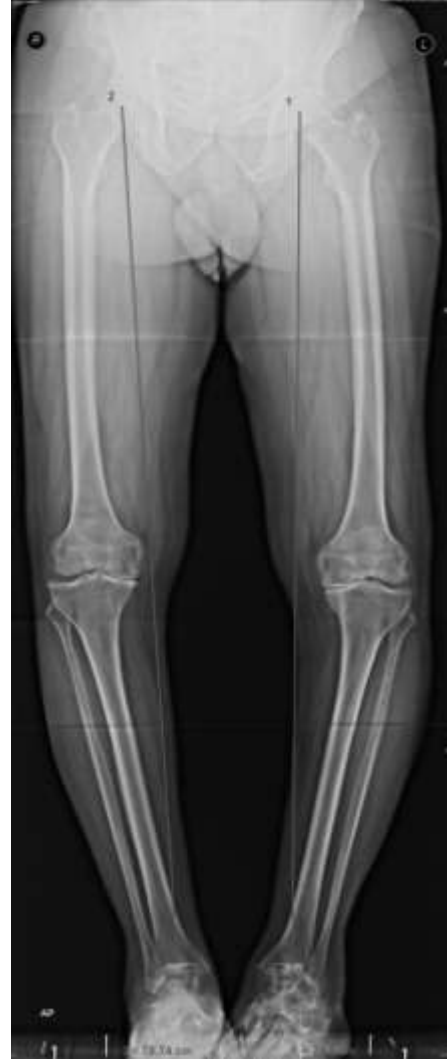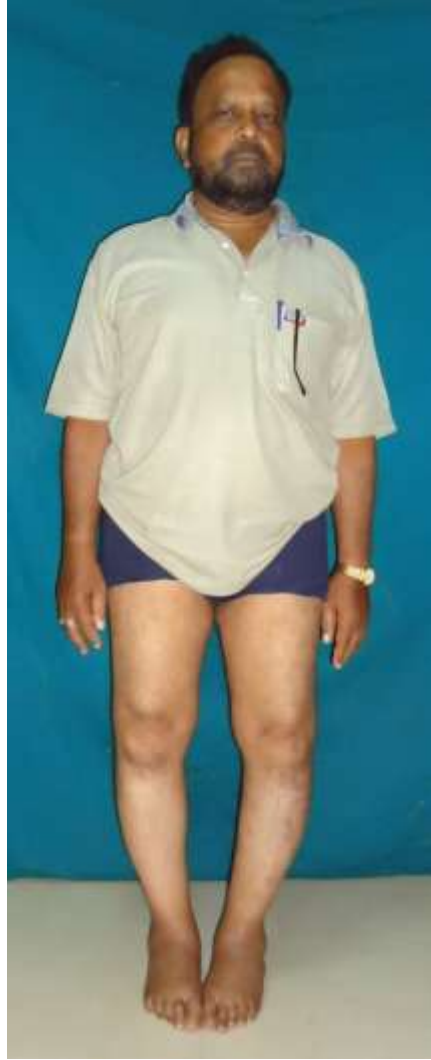# Matching of groups

MPTA, HKA, FTA, MAD.....all similar

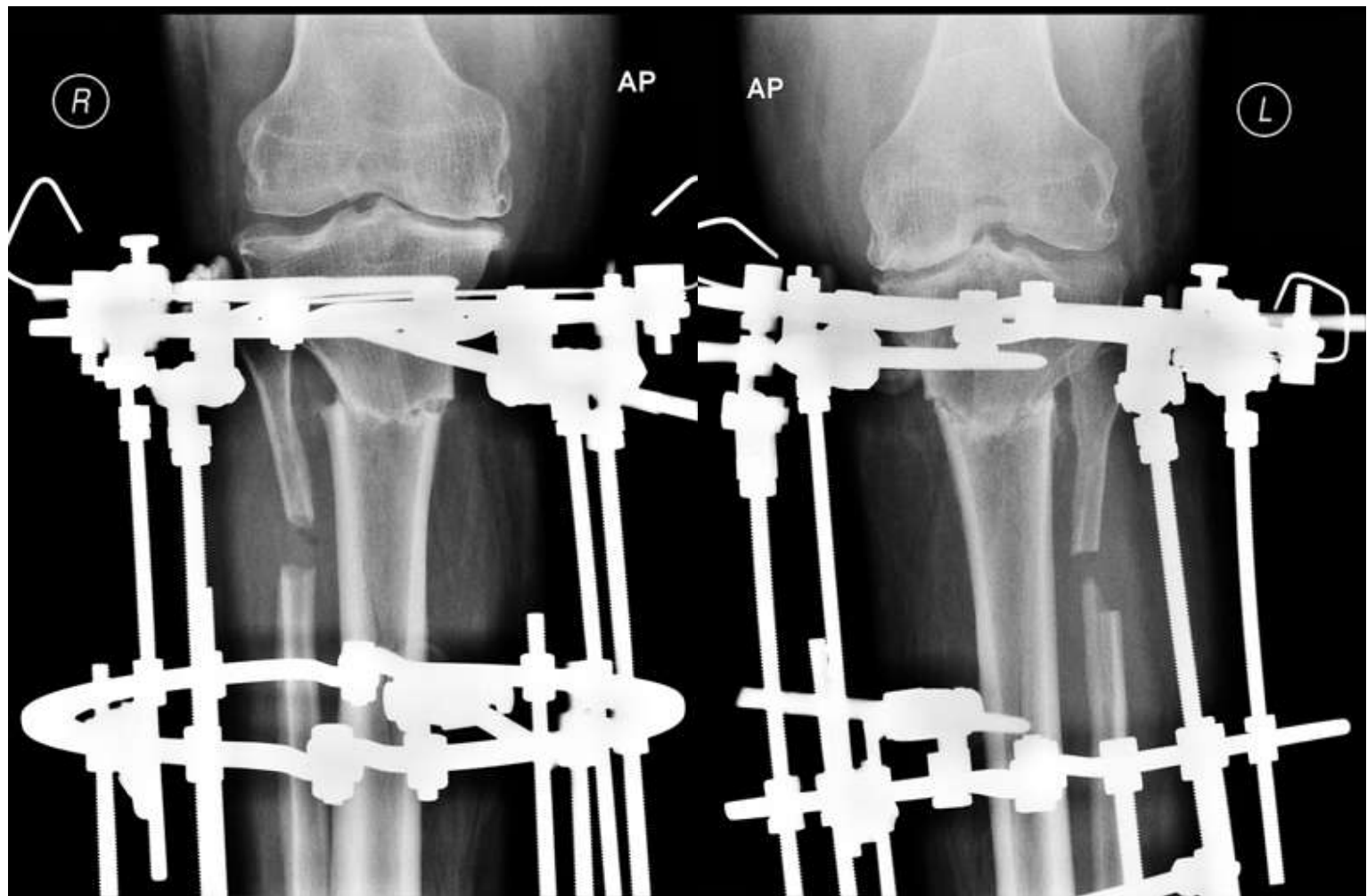Age.....older in FAP

Females.....more in FAP

Both Groups were well matched. Xray measurements were similar preoperatively with no statistical significant difference in the deformity parameters.. FAP group were older and had more women. Only the PPTA was slightly different between the 2 groups. This was not a randomised study as we actually intended to perform the plating for order patients and as well as for women.



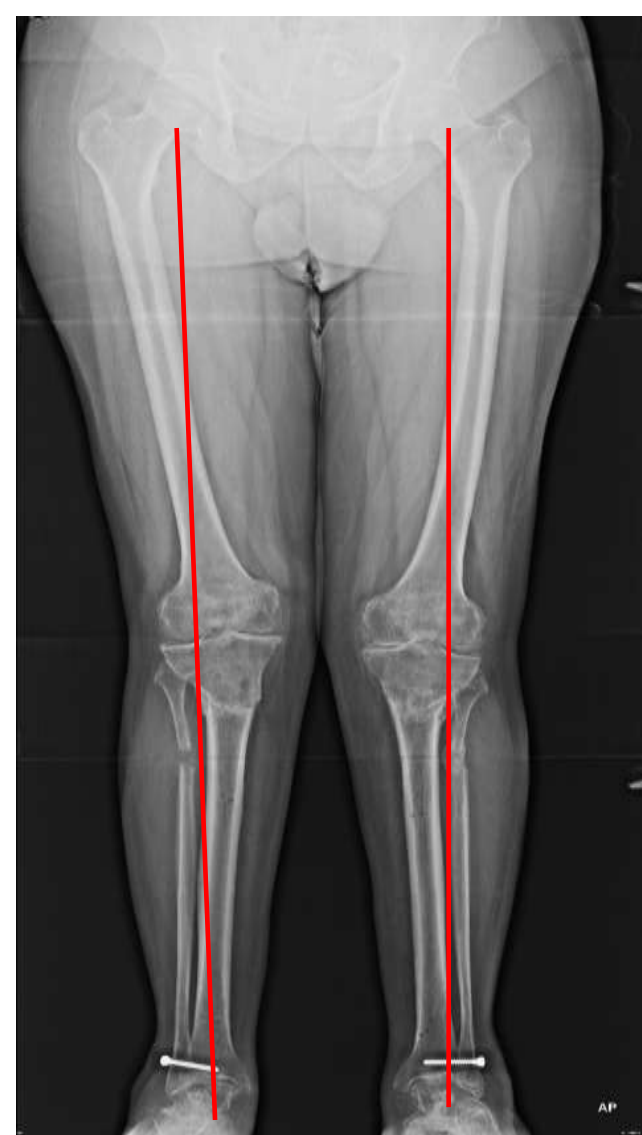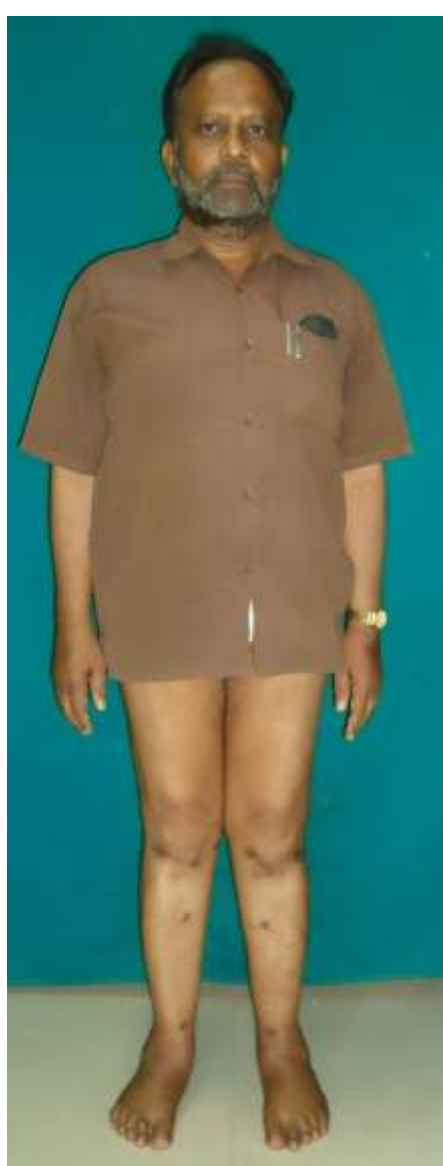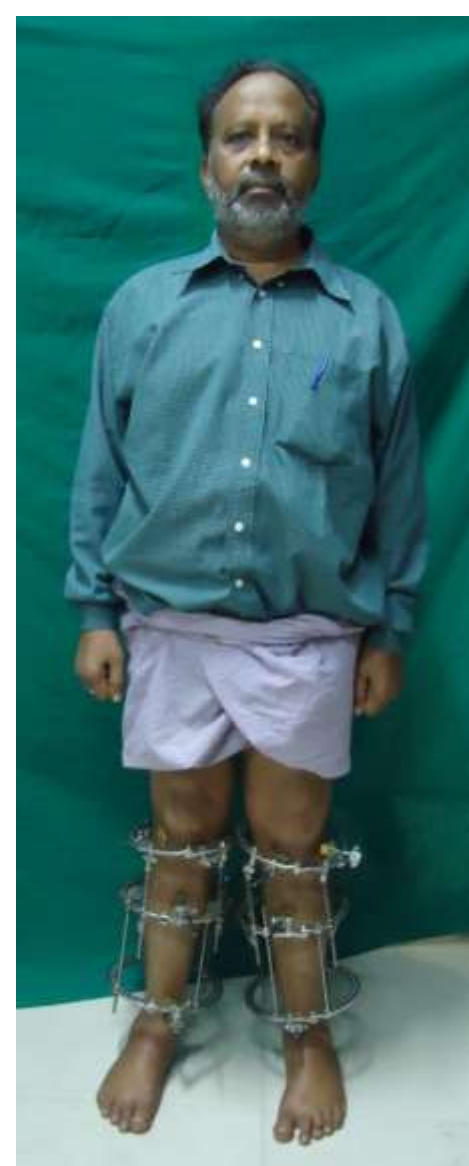55 yrs old , bil. medial compartment OA knee was advised to undergo a total knee replacement on both the knees at considerable cost. It was beyond his affordability and hence he chose to undergo a reliable high tibial osteotomy considering that he was only 55 years of age.



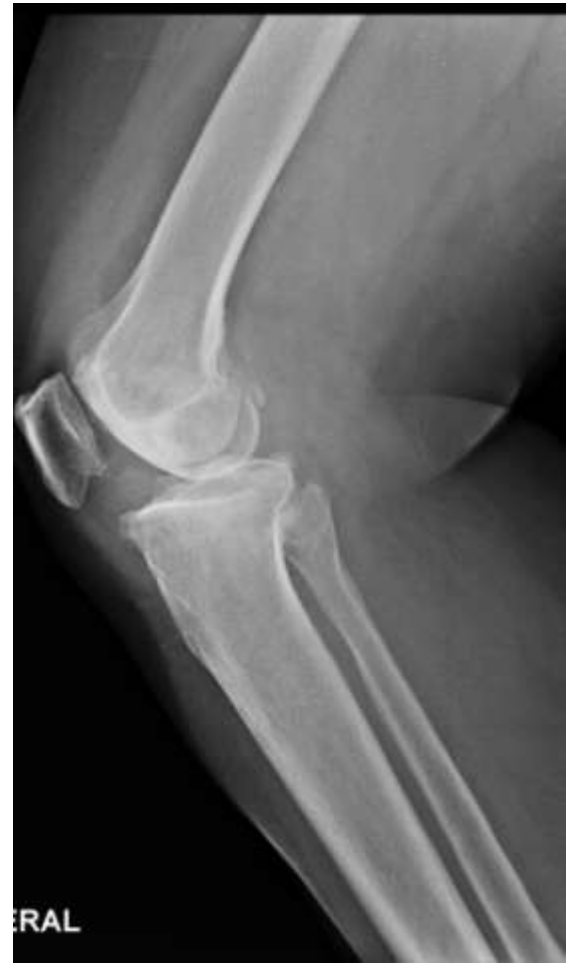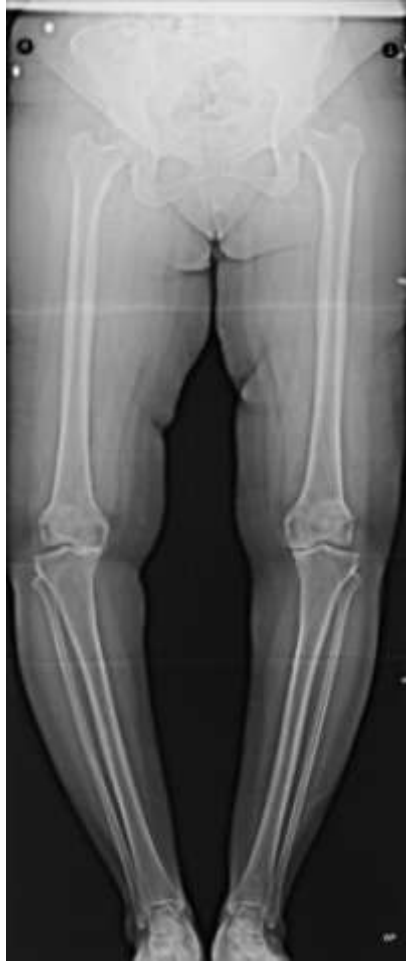Bilateral simultaneous surgery was done. The tibial osteotomy is percutaneous and fixed with a 3 ring frame. Fibula osteotomy is done at upper level. Bone contact is excellent.

The essential component of this osteotomy is to perform it in an arcuate manner and ensure that there is a very mild lateral translation of the distal fragment. This allows better lateral shift of the mechanical axis at the knee joint without having to perform a very significant amount of angular correction.

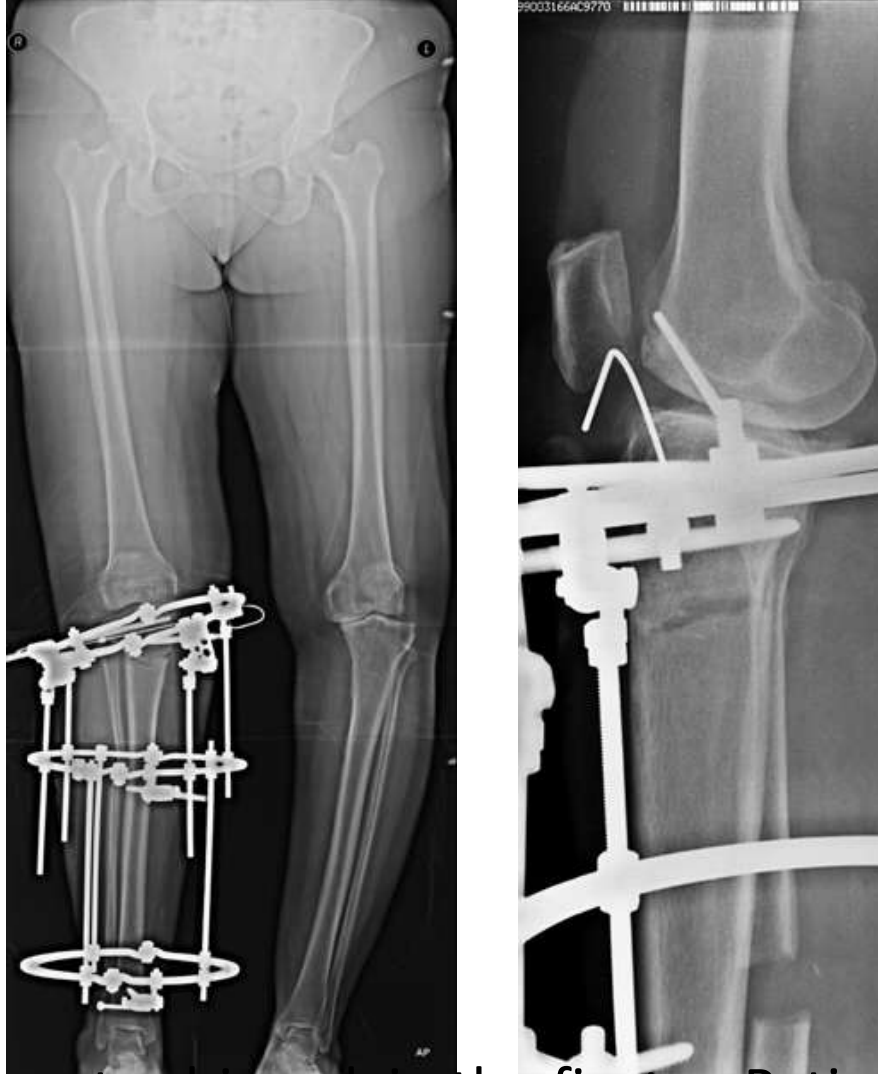The bony contact is excellent and hence union is achieved reliably in all.



Patient could walk well during treatment. Very good correction of mechanical axis seen into valgus. Patient completely free from pain.

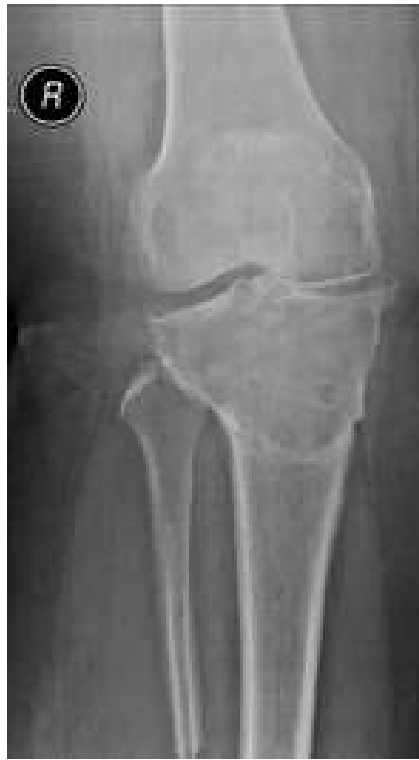
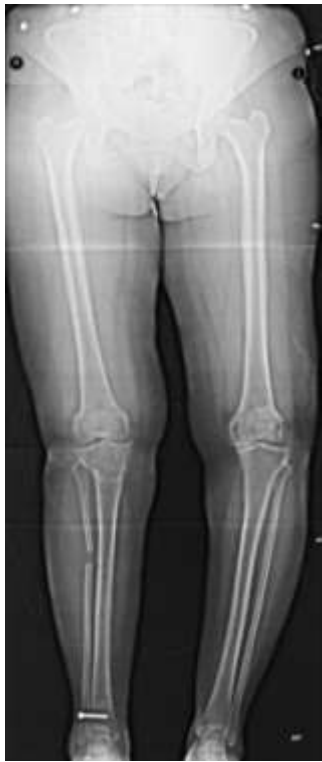
48 yr old lady with a large varus deformity. It would have needed 28mm opening wedge or 28mm resection of a closing wedge. Neither good options. Hence the Ilizarov Focal dome was the best choice. She is of course not a very good candidate for total knee replacement and she is very young.



Accurate alignment achieved in the fixator. Patient walking about comfortably and doing all her chores and was self sufficient. The great advantage of the Ilizarov fixator is that the alignment can be altered by watching the gait. A little excessive valgus is needed to all work on the dynamic valgus or the lateral thrust gait



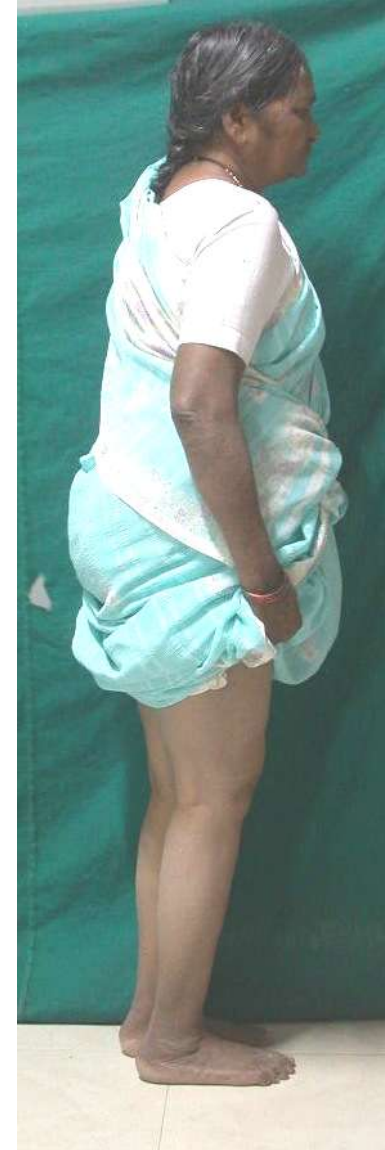
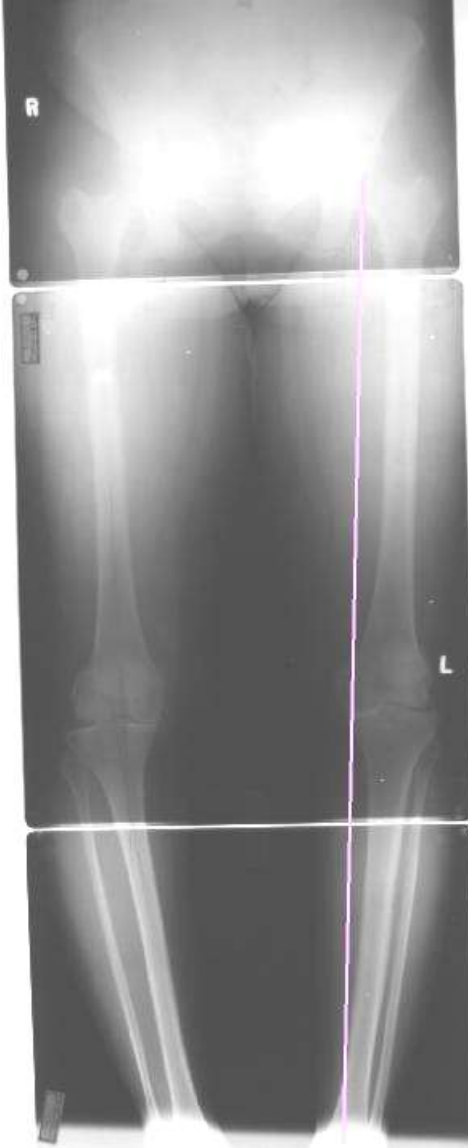
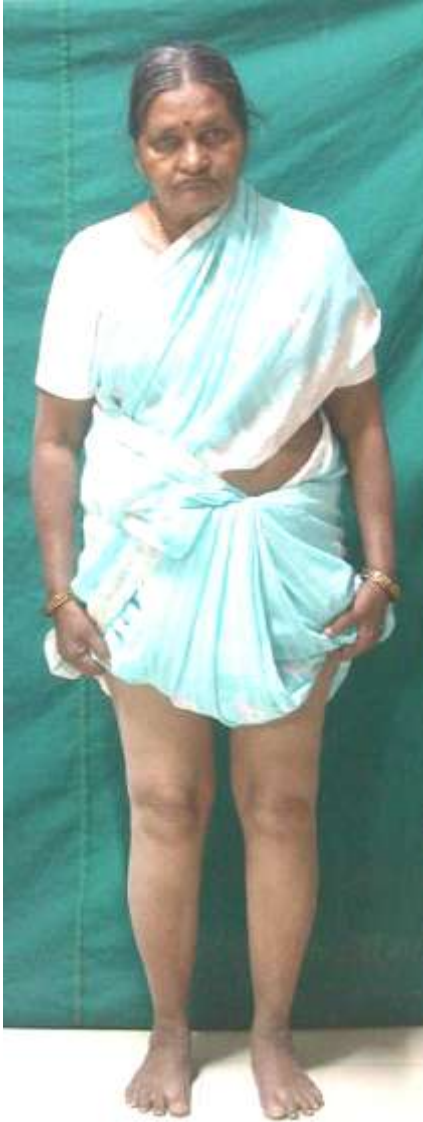14 weeks post op , osteotomy site healed well. Relief of pain keeps improving over the period of one year. The operation achieves the proper alignment and hence cartilage regeneration starts. The patient has to ensure good muscle strength by exercising and strengthening the quadriceps. Good Vit.D and calcium levels with proper nutrition is needed. The most important thing is alteration of gait by the patient. There was learn to perform minimum out toeing of the foot and ensure that the knee flexes slightly in the early stance phase of gait.

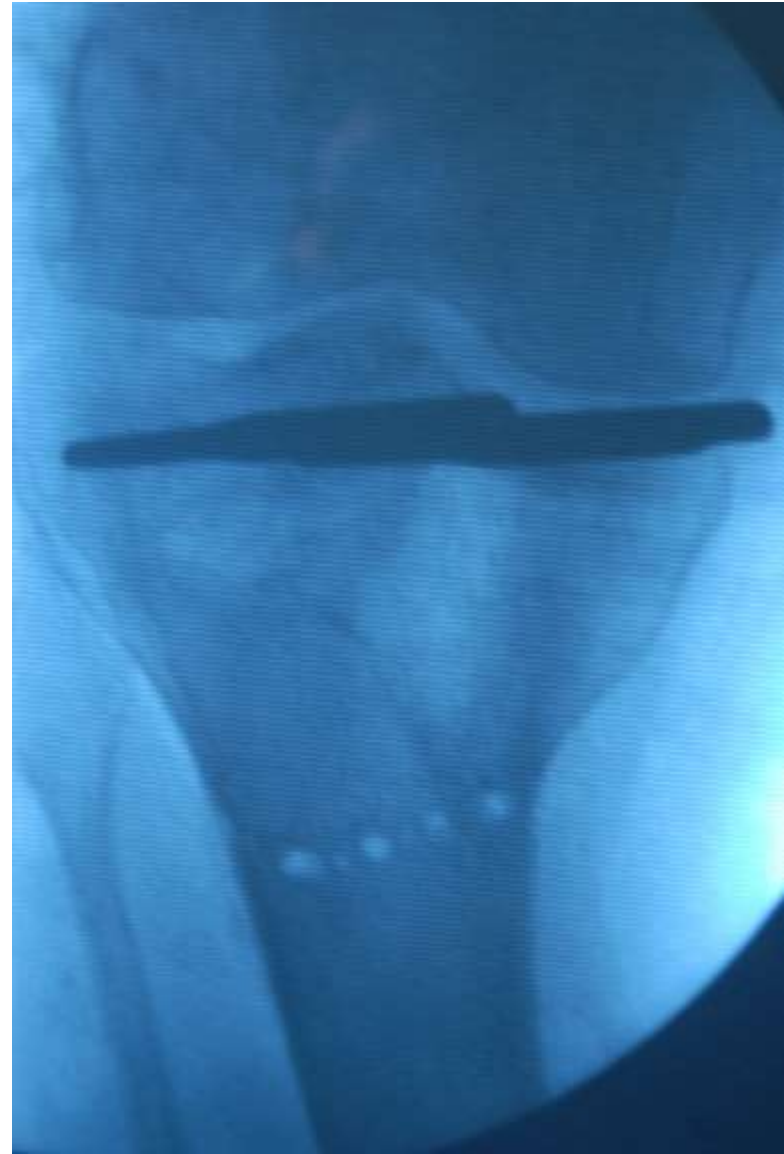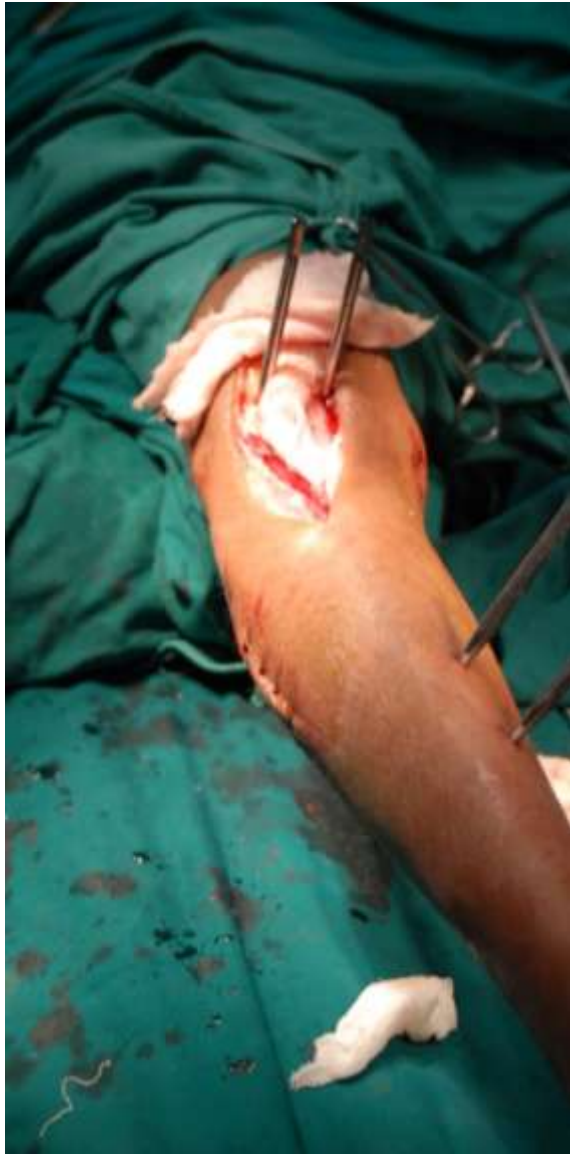# Fixator Assisted Plating

- Older : mean 59 yrs
- Not comfortable with ex-fix
- Significantly more variability in MAD before surgery

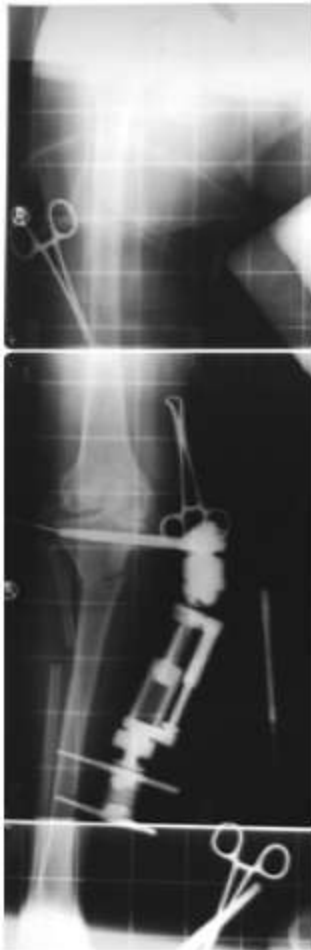With the availability of the Tomofix system we started performing the same osteotomy by using an external fixator for intra-op alignment only. The large number of movement and ordered patient's forward not be able to tolerate the fixator for the long duration that is needed to correct a large deformity. Hence there were chosen for surgery using the locking plate.



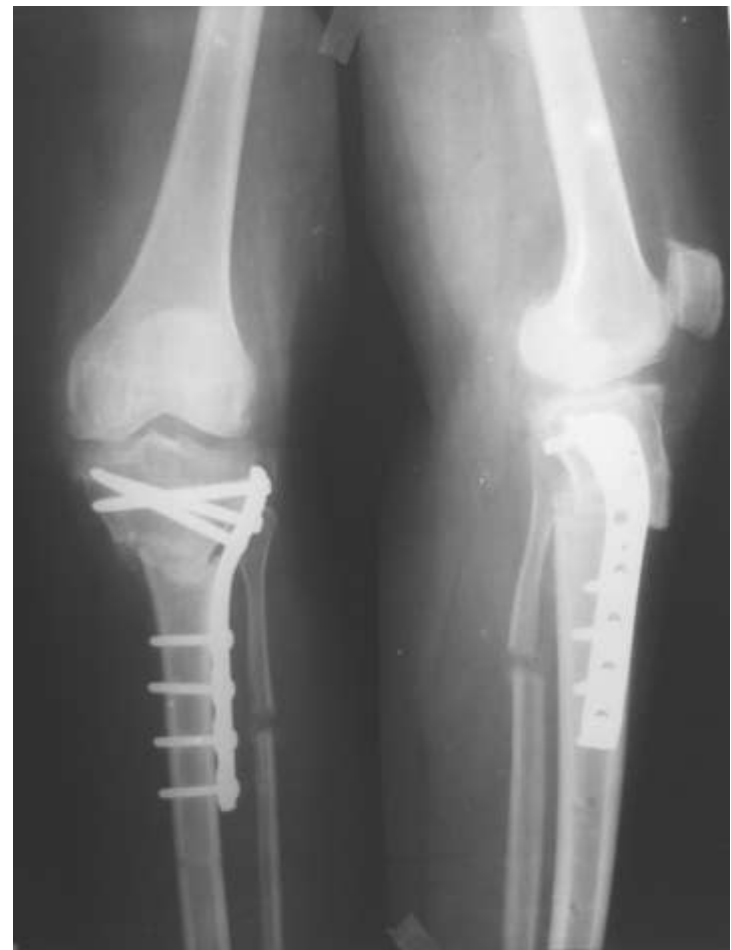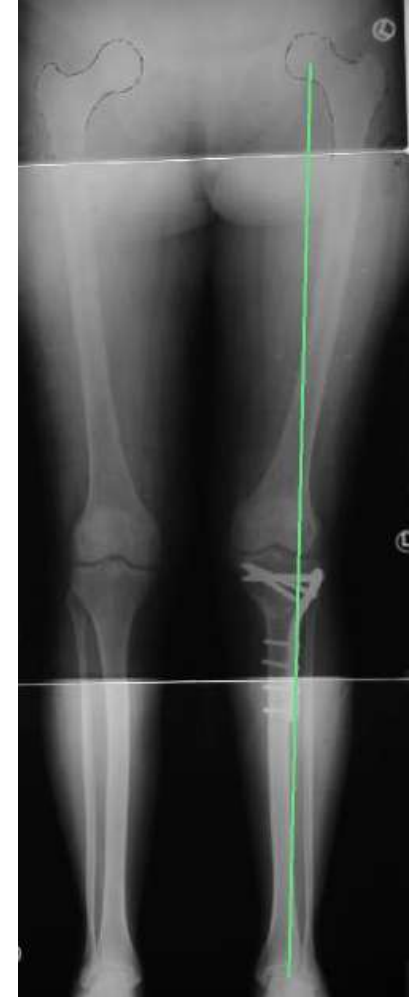65 yr old with large varus and severe pain. She is not a good candidate for opening wedge or an ex fix. Obvious acute financial reasons she is not a good candidate for total knee replacement as well.



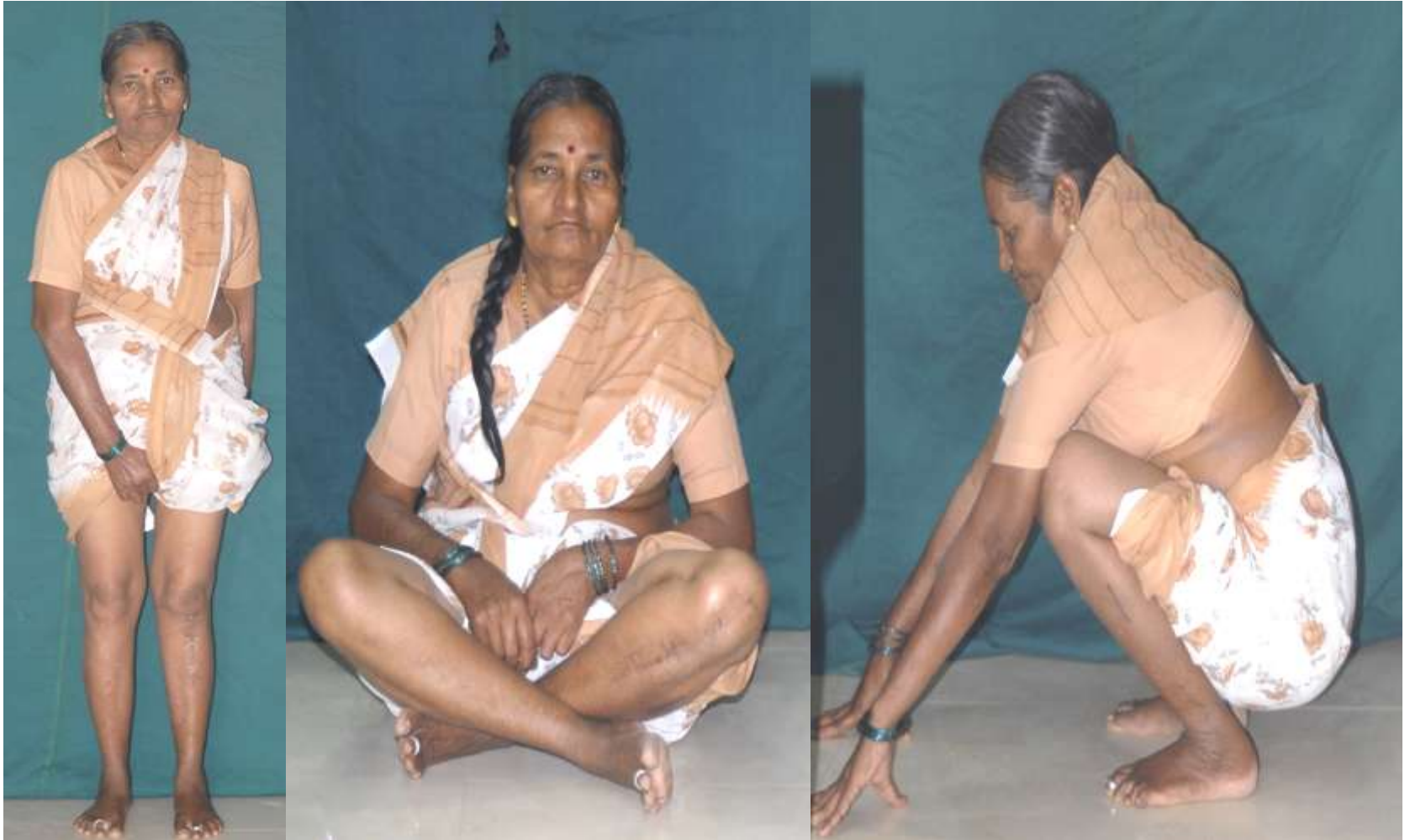Fibula osteotomy done. Open incision taken. Temporary exfix applied in OR. Outline of Focal Dome osteotomy made using drill holes. He does on the lateral or Ilizarov external fixator is attached to these half pins and after the osteotomy is completed the alignment is maintained with the external fixator



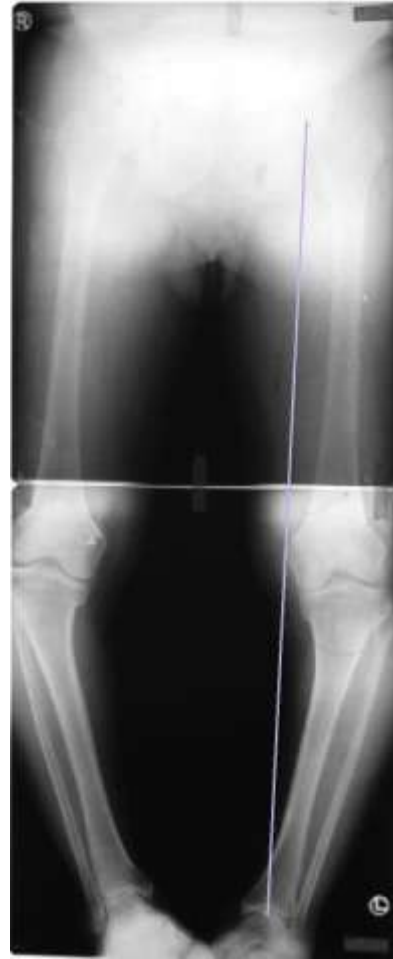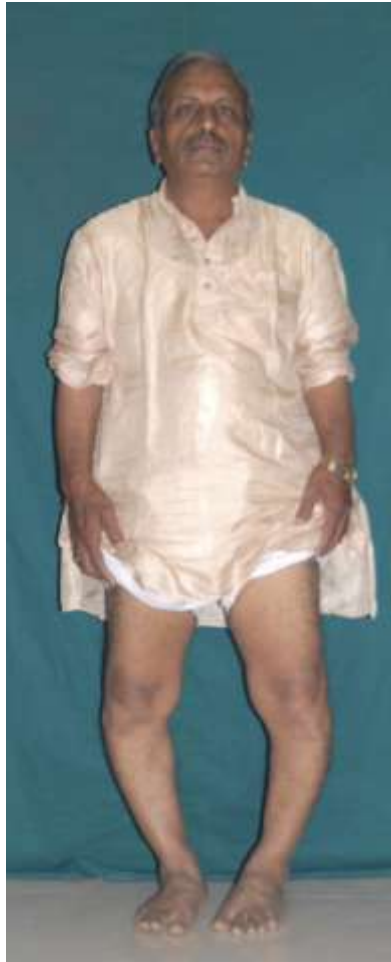We have a special portable xray machine and large cassette to check accuracy of intraoperative alignment. once the alignment is proper then the lateral normal fix plate is inserted and fixed with 6-7 locking screws. The conformal dose that can make a assessment of the alignment disregard the sandbag under the trochanter, the thickness of the tourniquet on the tie, the gap between the calf and table caused by the diameter of the doing, and the presence of a fixed flexion deformity.



Perfect alignment of mechanical axis thru Fujisawa point . Dome osteotomy just below tibial tuberosity with minimal lateral and posterior translation of distal fragment. Notice the minimal lateral and posterior translation of the distal fragment and the posterior translation is caused by external rotation which also helps in reducing the high adduction moment arm of gait

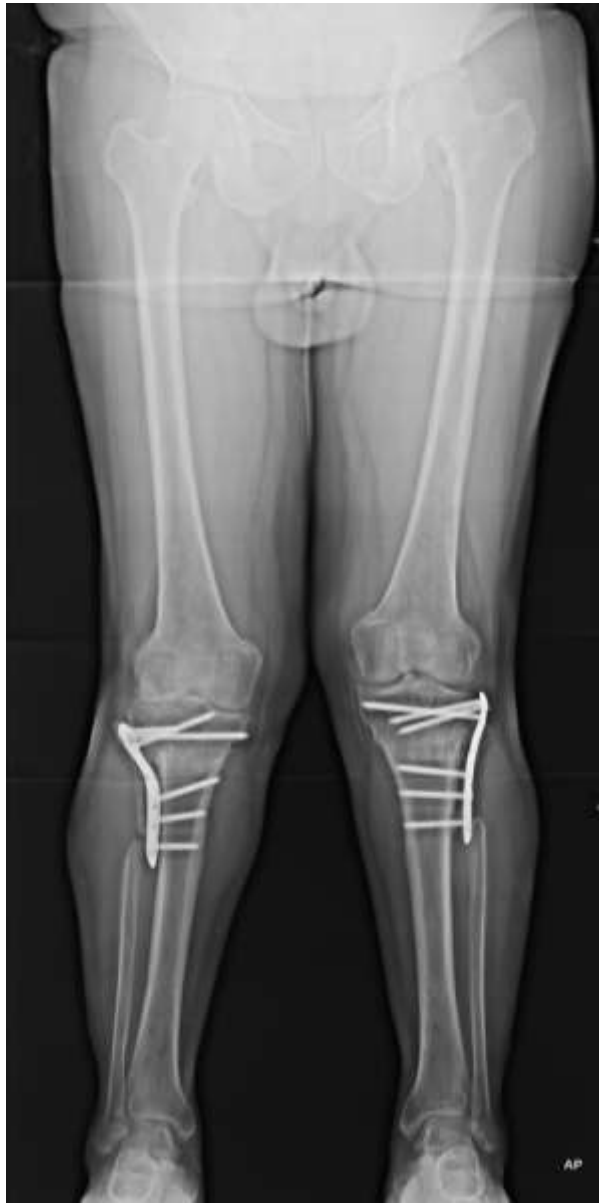
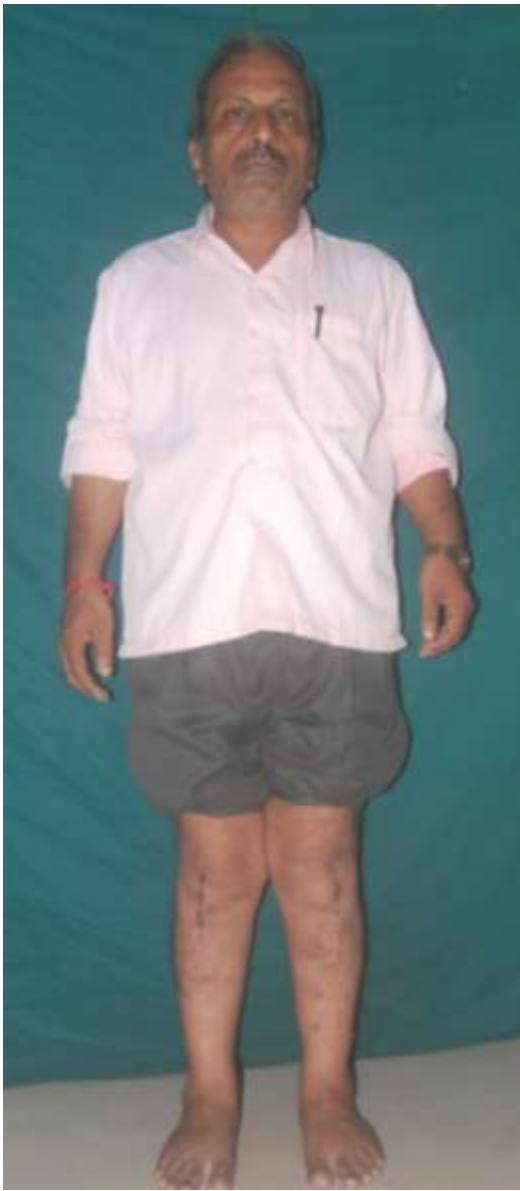
Pt is able to squat & sit cross-legged. she has no pain 5 years after the surgery

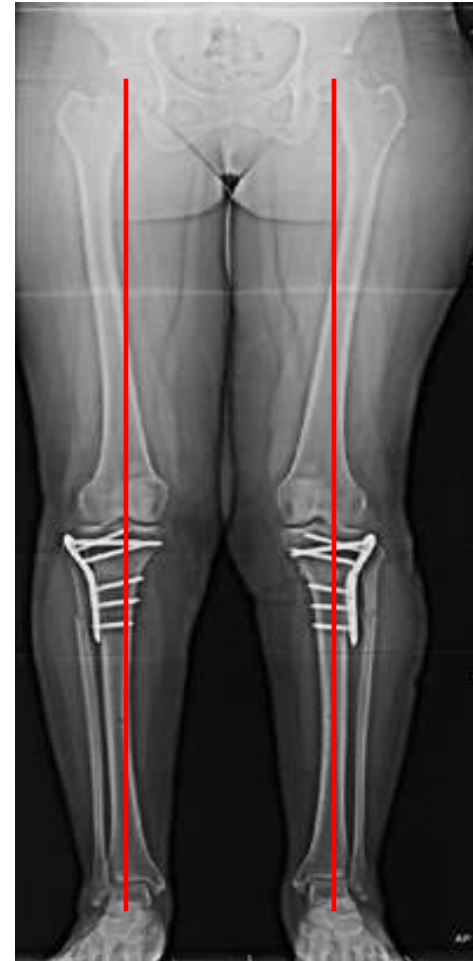
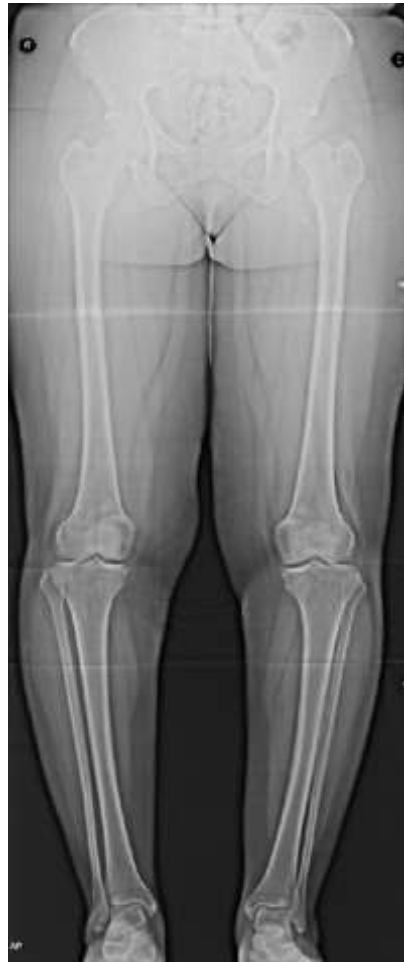
65 yrs old , b/l severe varus deformity of knee





Surgery performed one by one. Excellent alignment and relief of pain.



Not a candidate for external fixation as she had to go back to Namibia within a month. Surgeries performed within two weeks of each other. Could walk full weight bearing despite weighing 85kg weight . Good alignment and relief of pain.

# Statistics

Test	Ilizarov	FAP	p value
PO MPTA	96.7 <sup>0</sup>	93.58 <sup>0</sup>	0.0034
PO HKA	174 <sup>0</sup>	177 <sup>0</sup>	0.0418
PO FTA	169 <sup>0</sup>	172 <sup>0</sup>	0.0493
PO MAD	69.3 %	54.90 %	0.0154
PO PPTA	81.1 <sup>0</sup>	81.1 <sup>0</sup>	0.990

Statistical analysis was done with the Mann Whitney test which showed that all parameters like MPTA ( which shows proximal tibial angulation), The Femoro-Tibial Angle FTA which is the Anatomical axis alignment, the HKA which si the Mechanical Axis Alignment and the MAD, which is Mechanical Axis Deviation were all more in Valgus with the Ilizarov external fixator group. On the Lateral xray, the tibial slope was similar in both the groups and did not adversely affect it.

# FAP

➤ Safe & Accurate Correction of valgus

in

Older females + larger varus deformities

In Conclusion, Fixator assisted plating was used for older patients and could correct large varus deformities. I will there was a large variation in the post-operative valgus and the mechanical axis using the plating method. There also tended to be correction into slightly very less valgus as compared to the Ilizarov group

These disadvantages were offset by the greater convenience and comfort of the locking plate fixation. The notable feature is that the pulp of explained to saw strong that the patient was able to bear full weight on the limb much before proper bony union

# Ilizarov

- More Reliable.
- Dynamic Varus correction so more Valgus.
- Younger patients.

Ilizarov ex fix is very reliable, non-invasive and gives better correction of static and dynamic varus and is well tolerated by younger patients. There is no need for a blood transfusion and the incision site was a very small the notable aspect or the alignment is that significantly more valgus is achieved as can be measured by the MPTA, the FTA & and mechanical axis deviation.

This exotropia is an indicator of the moment of correction needed to overcome the lateral thrust gait.

**Thank you.**