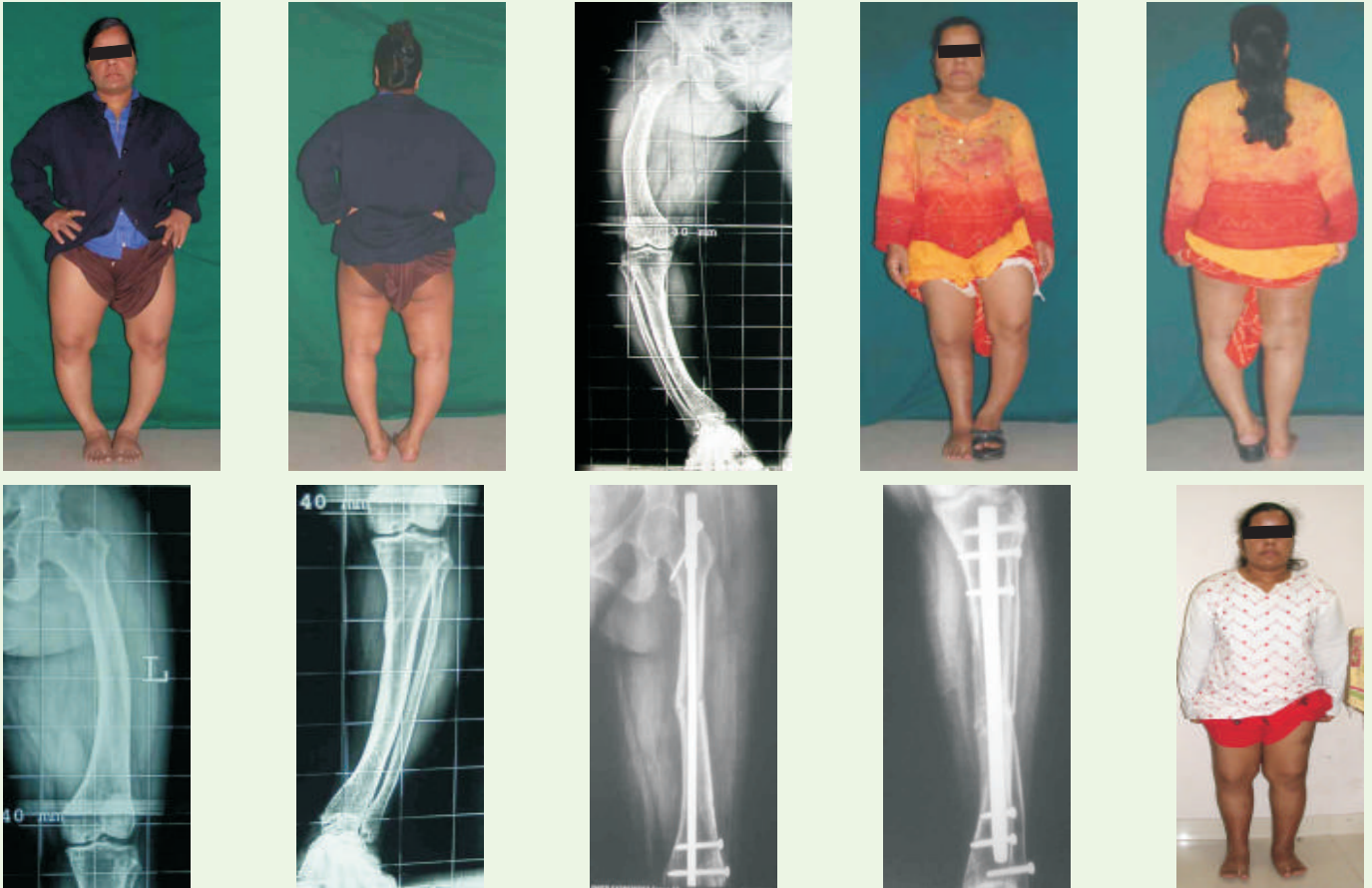
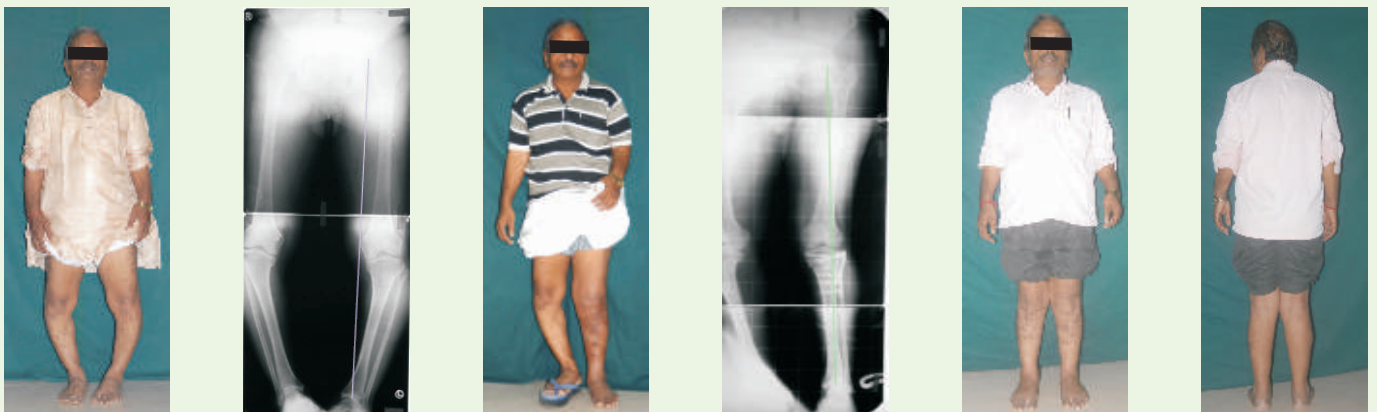

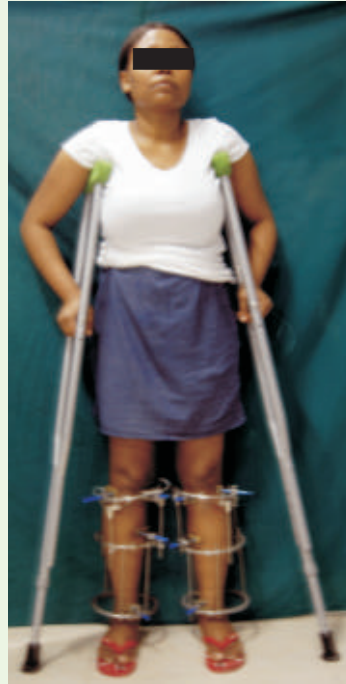## Bow Legs



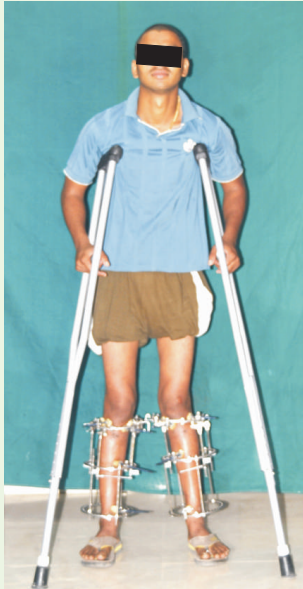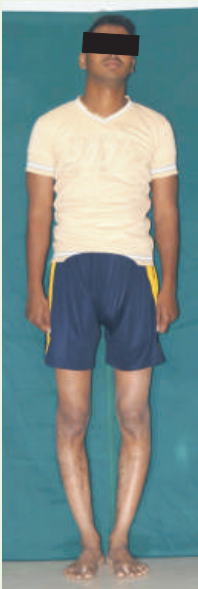37 year old physician had Rickets with severe bow legs. She had difficulty in walking with pain in the knee. Full length xrays showed significant varus bowing deformity in the midshaft of both the Femur & Tibia bones. The right leg was corrected initially with the Ilizarov fixator in femur and tibia. The correction achieved was complete and accurate. Due to rickets bone healing in the corrected position took a long time. In order to reduce the duration of the fixation, we performed correction using IM nailing in the left leg. though the surgery was longer, healing was uneventful and correction was very good.



56 year old Insurance executive had severe bowing deformities in the both limbs. His full length xrays showed the deformity to chiefly arise from the tibia bones. Fixator assisted Plating operation was performed on him, on leg at a time. In surgery, the ilizarov fixator is applied using Titanium pins. The osteotomy or cut in the bone is done as a dome. The fixator then allows us to accurately correct the deformity. This is checked with a full length xray taken on the operation table. Once accurate correction is achieved, the bone is fixed in its new position with a Synthes TOMOFIX Titanium-Niobium locking plate. He was able to walk within a few days of the surgery. After 5 months the other side was operated and he achieved full correction of his deformity.



35 year old PA from London was troubled by her bow leg deformity. Upon taking full length xrays, the deformity was found to be in the tibia bones. Since she was young, active & wished to have both legs operated upon on the same day, we chose to perform her correction using the Ilizarov external fixator. This is a minimally invasive surgery and the varus bowing deformity is accurately corrected with help of the Ilizarov External fixator with tiny incisions. She was able to walk with crutches on the second day of surgery and returned to London with the fixators on the 18th day. She returned to India to remove her fixator at the end of 3 months. Her correction was complete and she was happy with the result.



28 year old primary school teacher from Nagpur was suffering from severe knee pain due to Bowing deformity. Full length xrays revealed the deformity to arise from the tibiae below the knee. Both legs were operated upon at the same time and accurate correction of the deformities was achieved using the Ilizarov external fixator.